

**Imagerie des lésions
musculaires et tendineuses
traumatiques du mollet.**

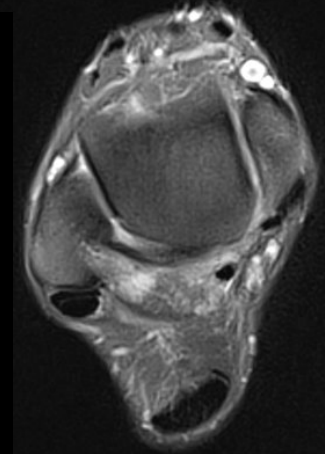
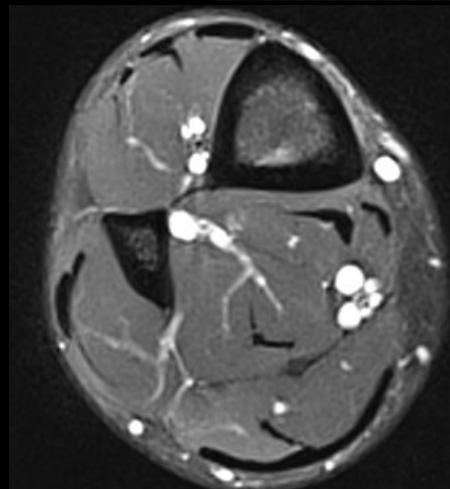
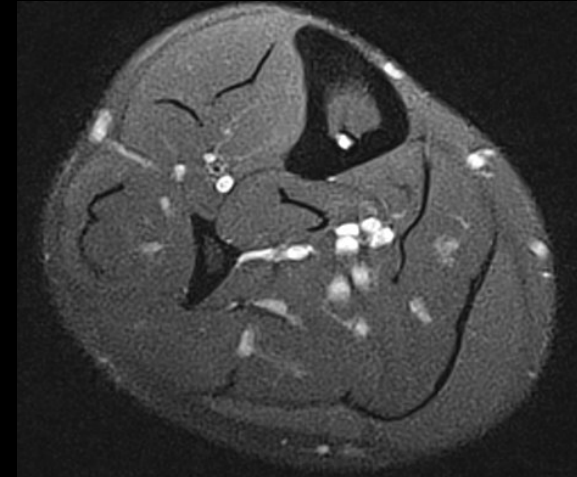
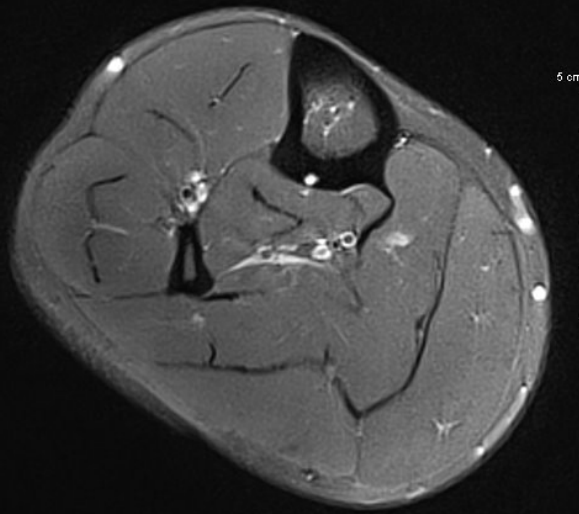
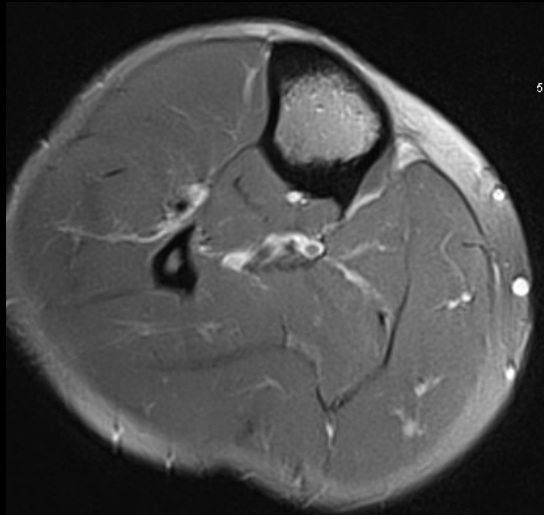
Yannick Carrillon

Département d'Imagerie

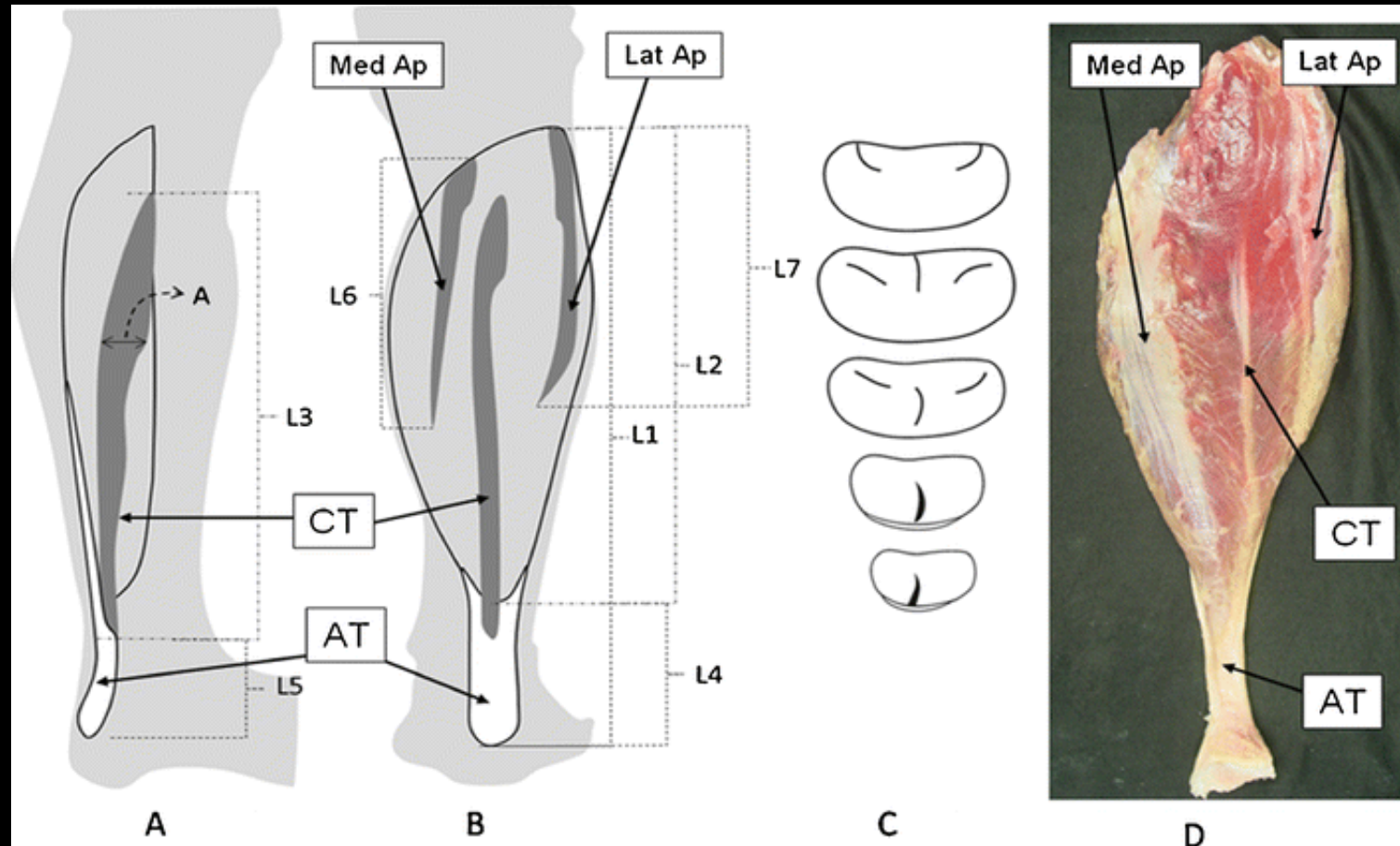
Centre Orthopédique Santy

Lyon

Anatomie musculaire du mollet.



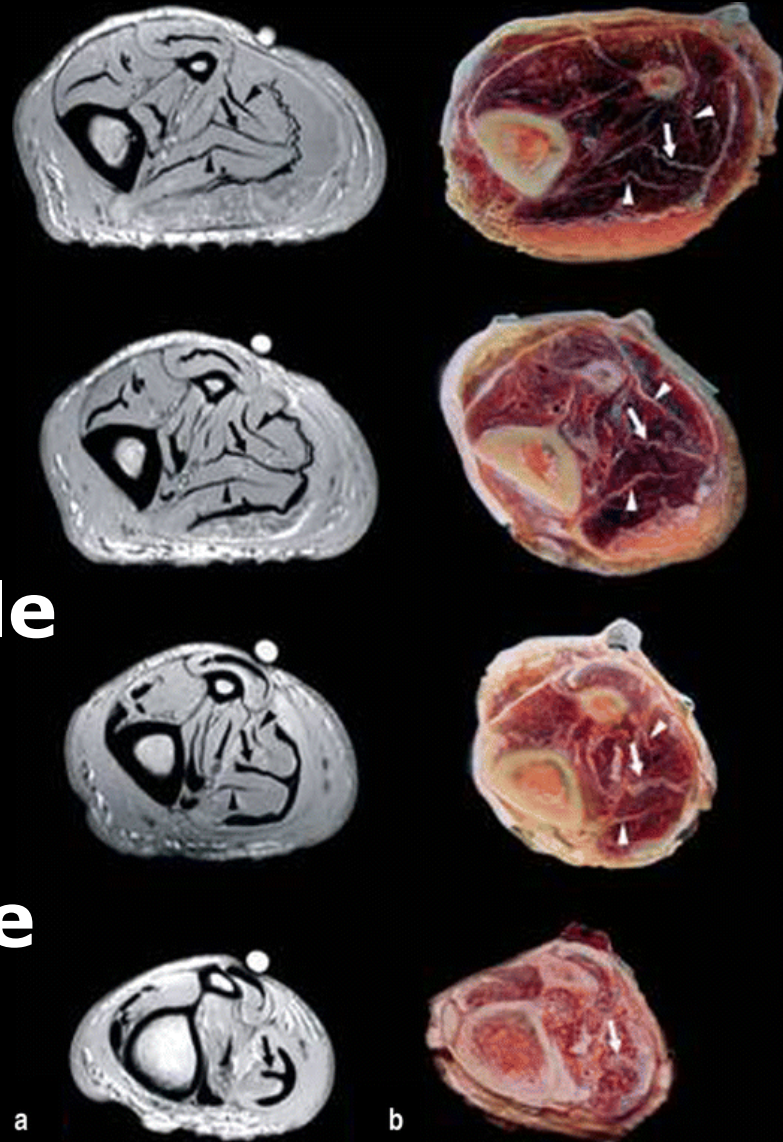
Anatomie musculaire du mollet.



R. Balius. Skeletal Rad 2012.

Anatomie musculaire du mollet.

- Cloison centrale
- Aponévrose centrale
- Aponévrose latérale



R. Balius. Skeletal Rad 2012.

Les lésions musculaires et tendineuses traumatiques du mollet.

- **Soléaire**
- **Tennis leg**
- **Jonction myo tendineuse et tendon calcanéen.**
- **Autres...**

Les désinsertions myo aponévrotiques du soléaire.

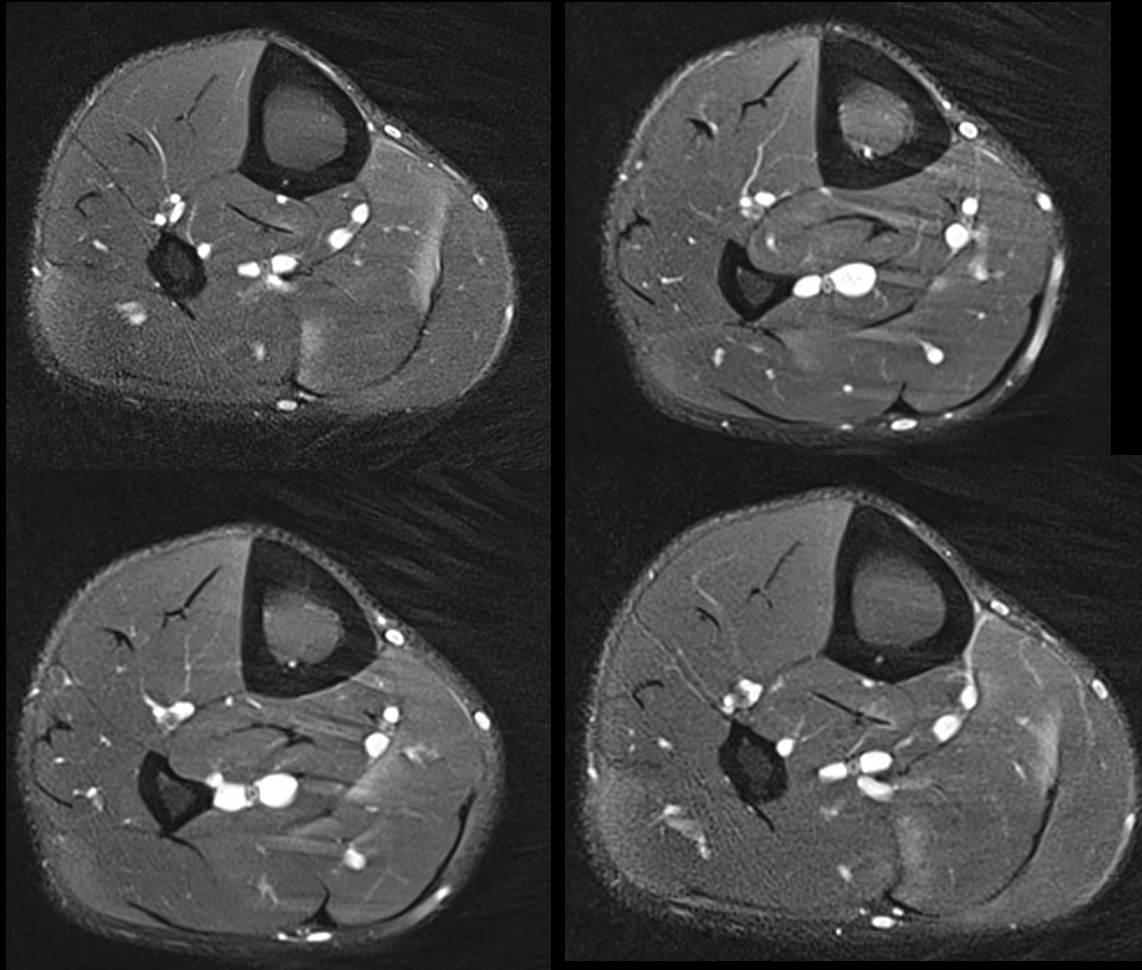
- **Centrales +++**
- **Périphériques**

Les DMA centrales du soléaire.

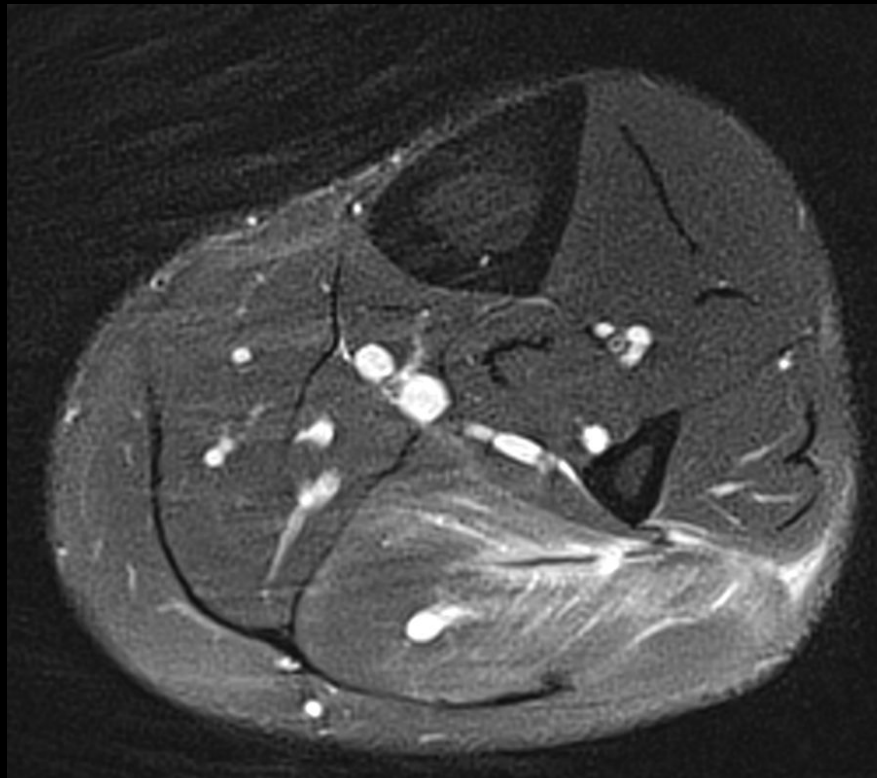
- **Difficiles en échographie**
- **Peu cliniques mais récidives ++**

Soléaire

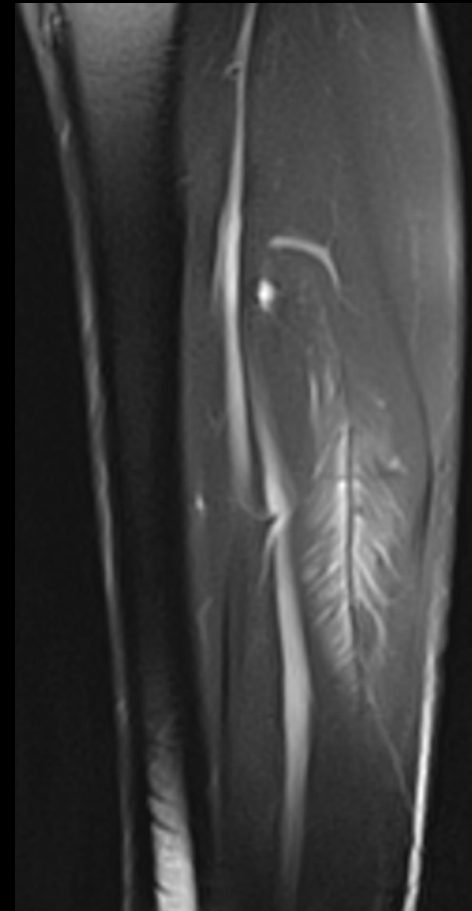- **Grade 1** : œdème mal limité (DOMS).



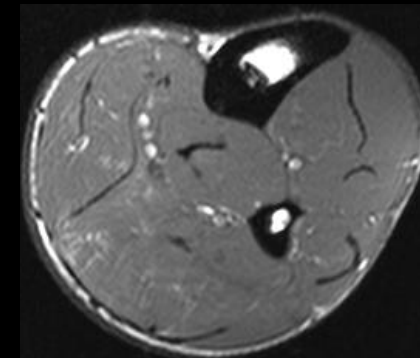
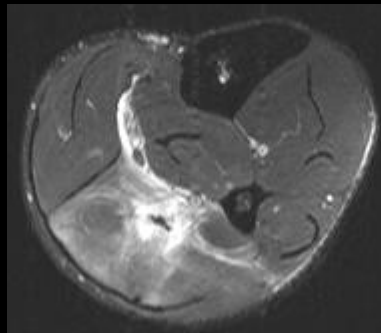
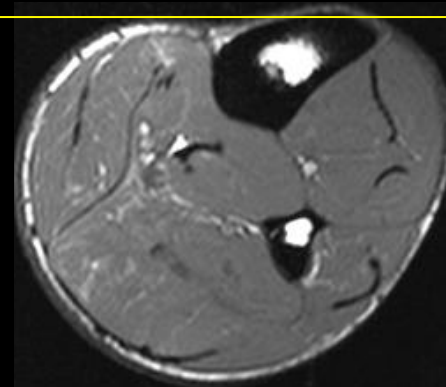
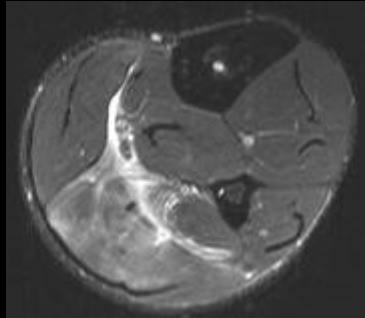
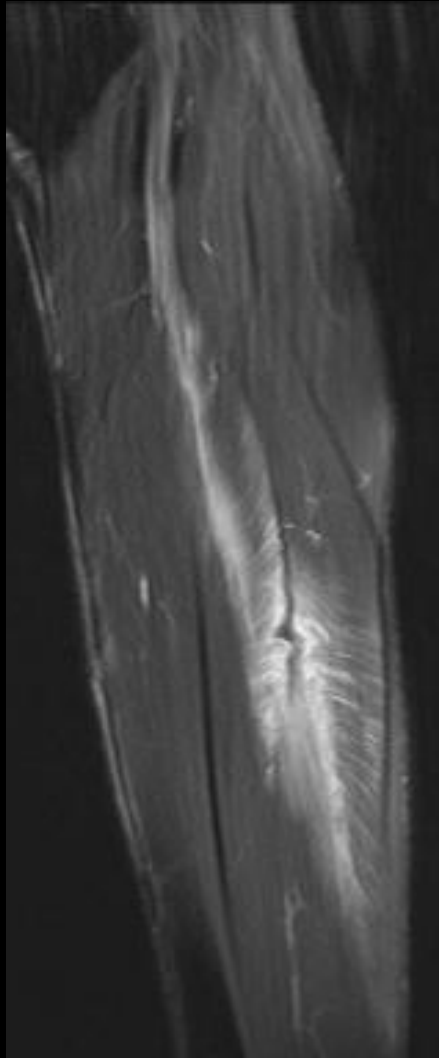
Désinsertion myo aponévrotique centrale du soléaire sans rétraction.



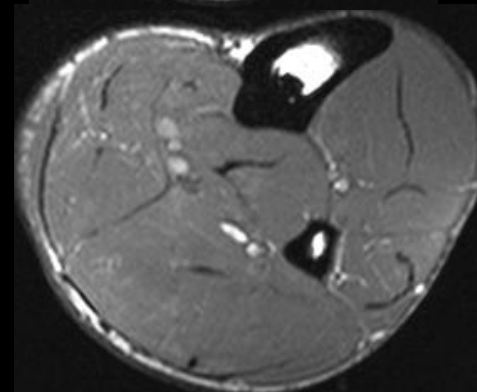
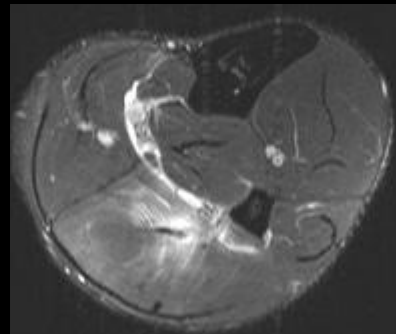
Stade 3



Désinsertion myo aponévrotique centrale du soléaire avec rétraction.

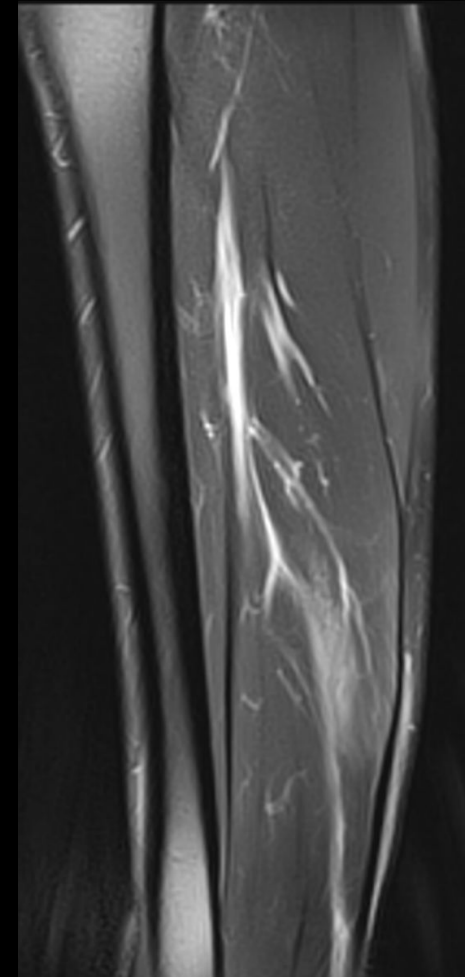
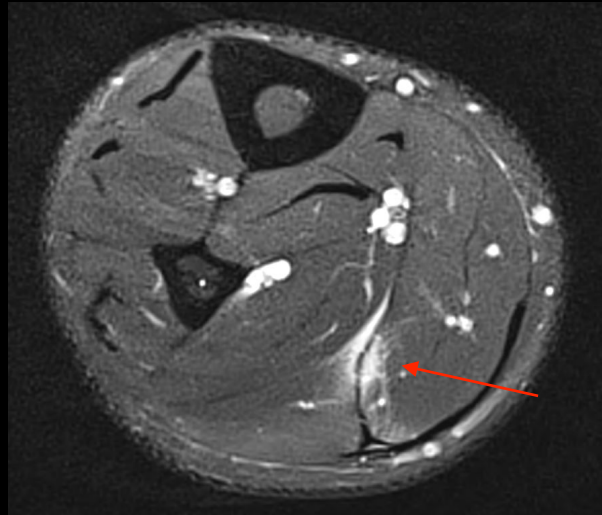
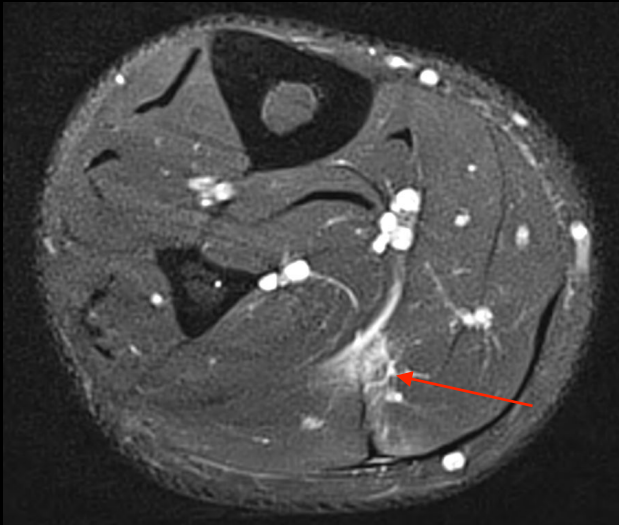


Stade 4



Désinsertion myo aponévrotique périphérique du soléaire sans rétraction.

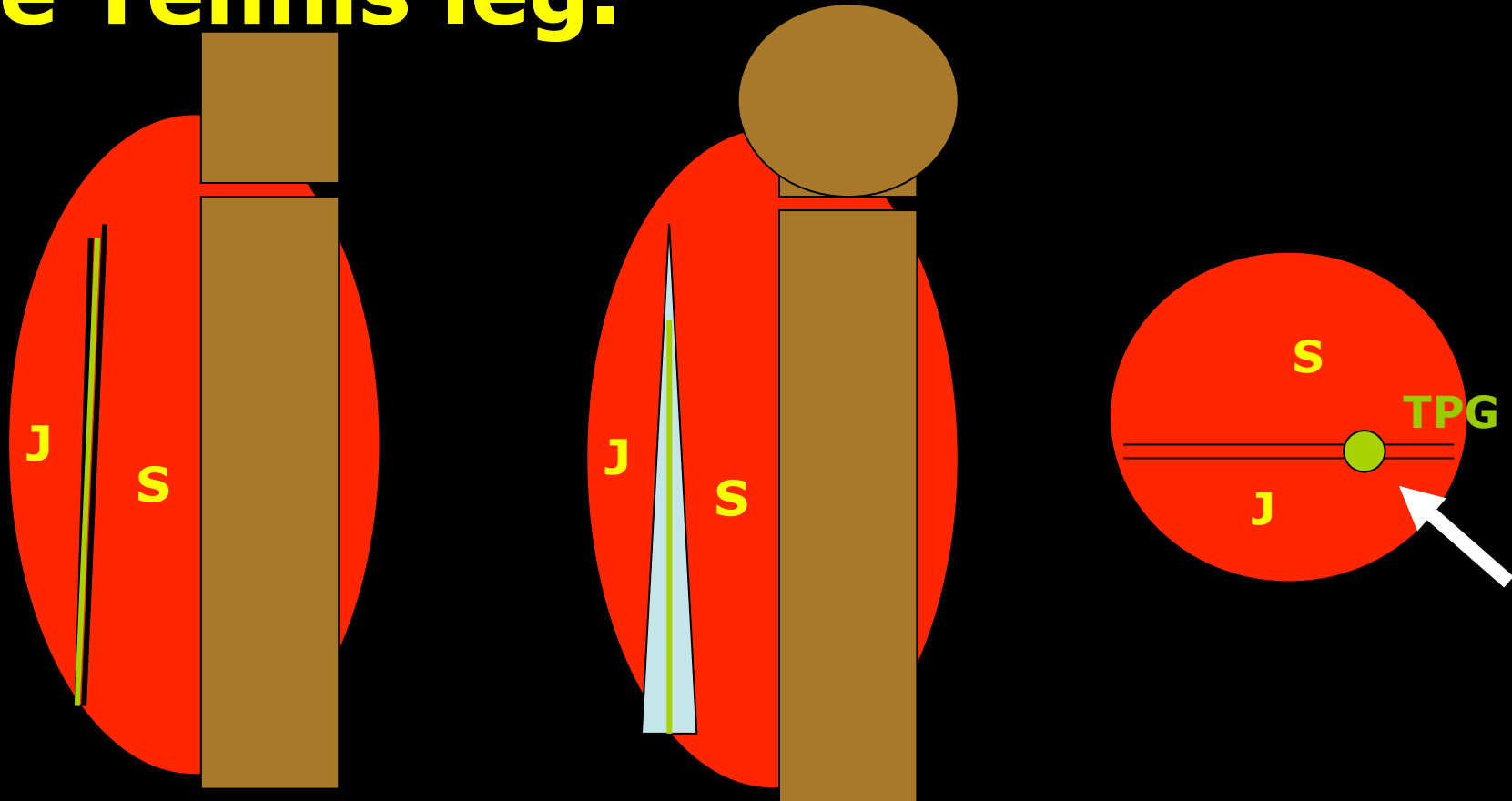
Stade 3



Le Tennis leg.

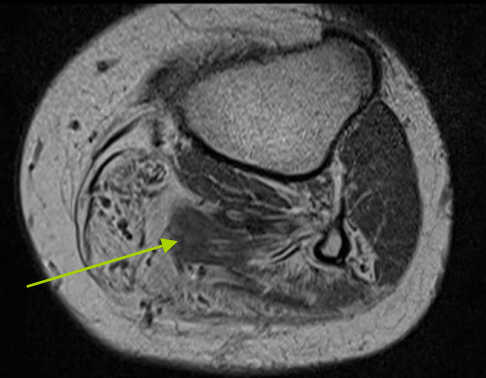
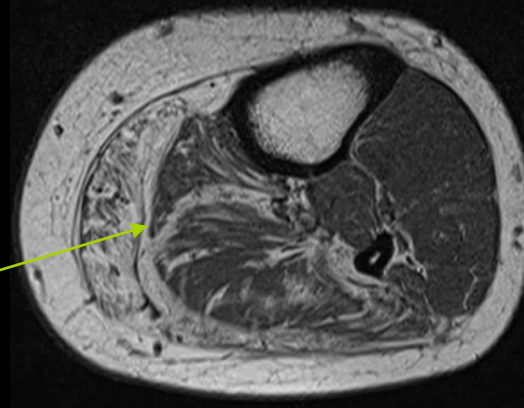
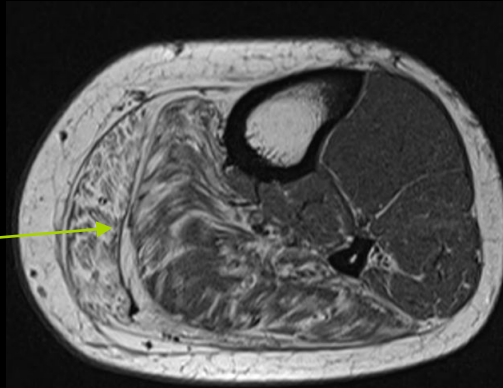
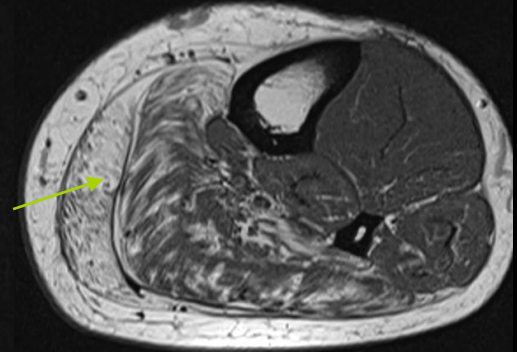
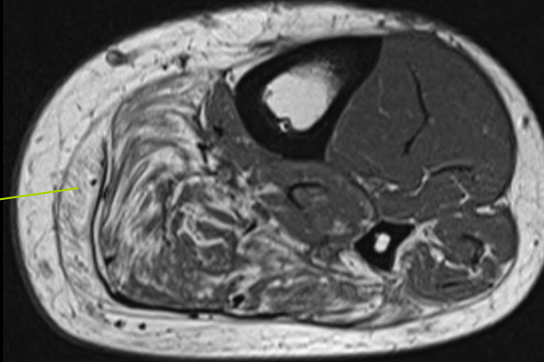
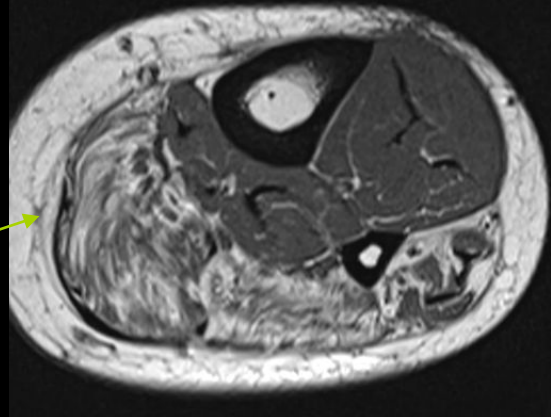
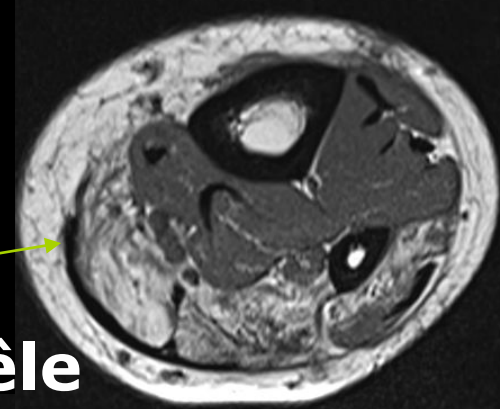
- **Décollement de l'aponévrose profonde du gastrocnémien médial.**
- **Zone de fragilité due au Plantaire grêle.**
- **Association possible avec DMA.**

Le Tennis leg.



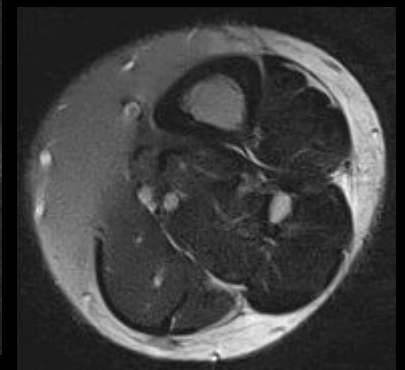
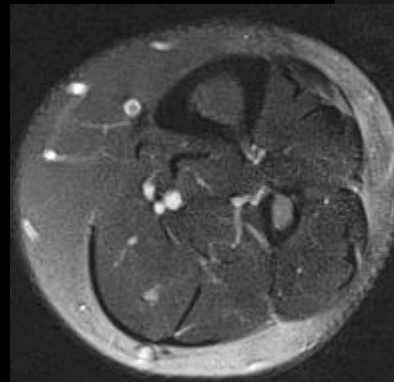
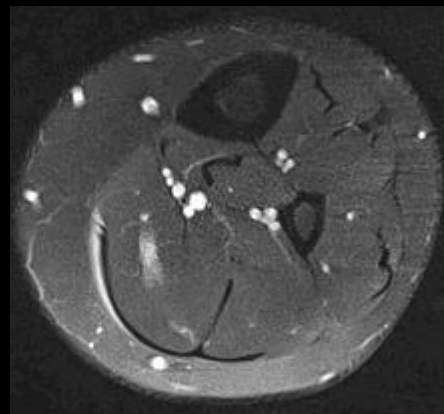
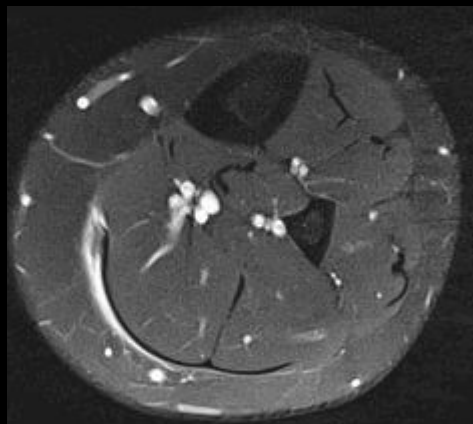
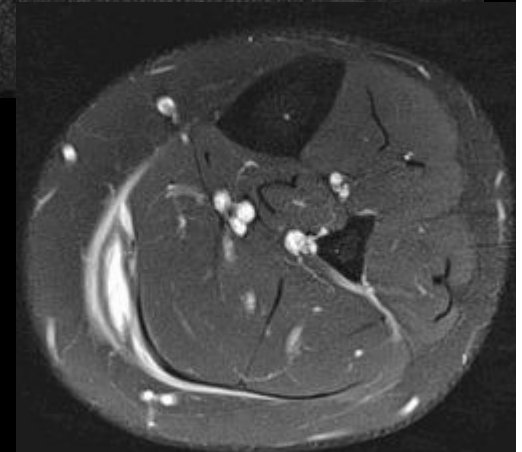
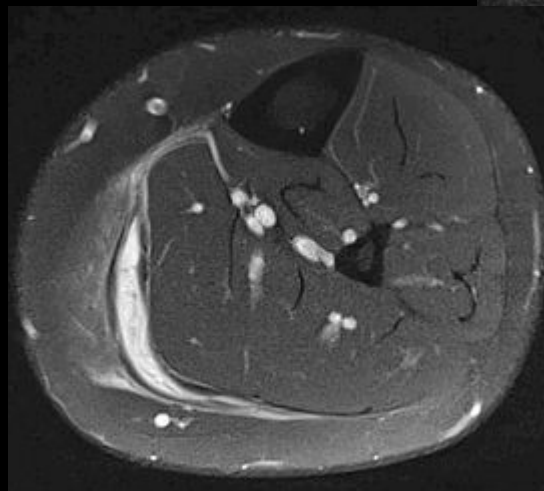
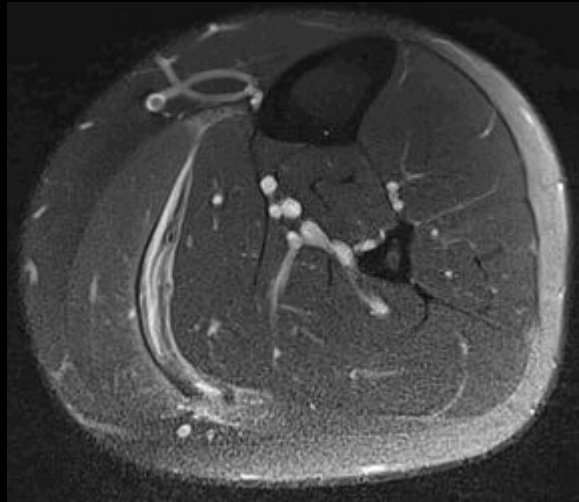
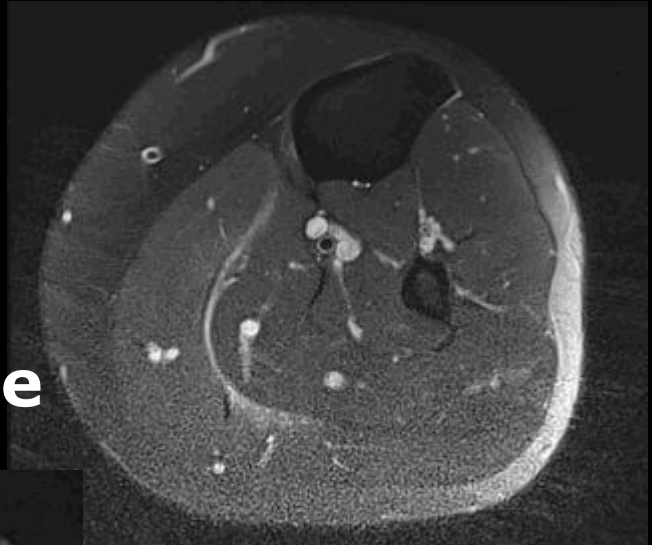
Le Tennis leg.

Espace virtuel du plantaire grêle

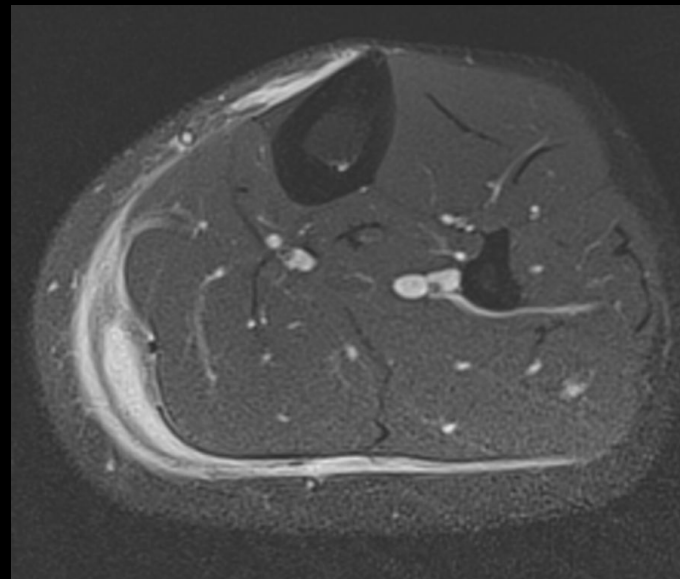
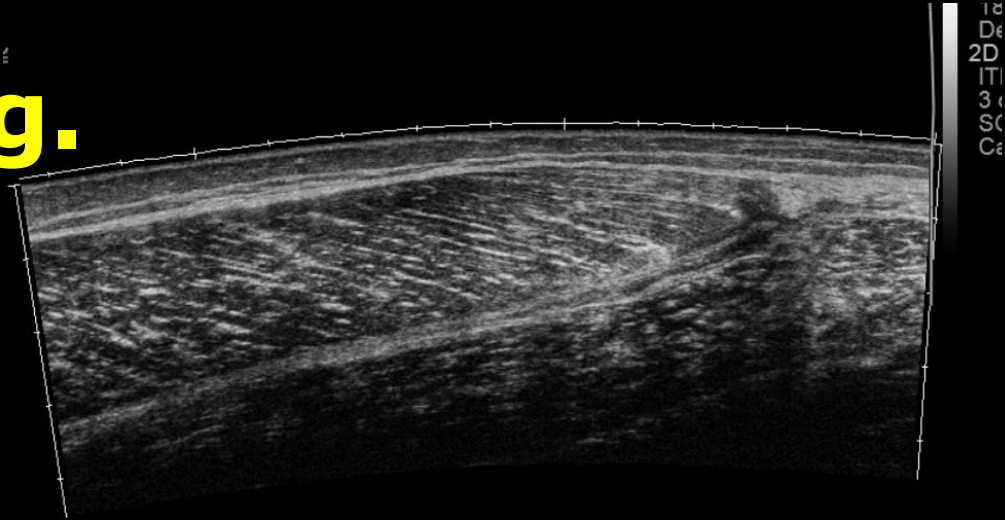
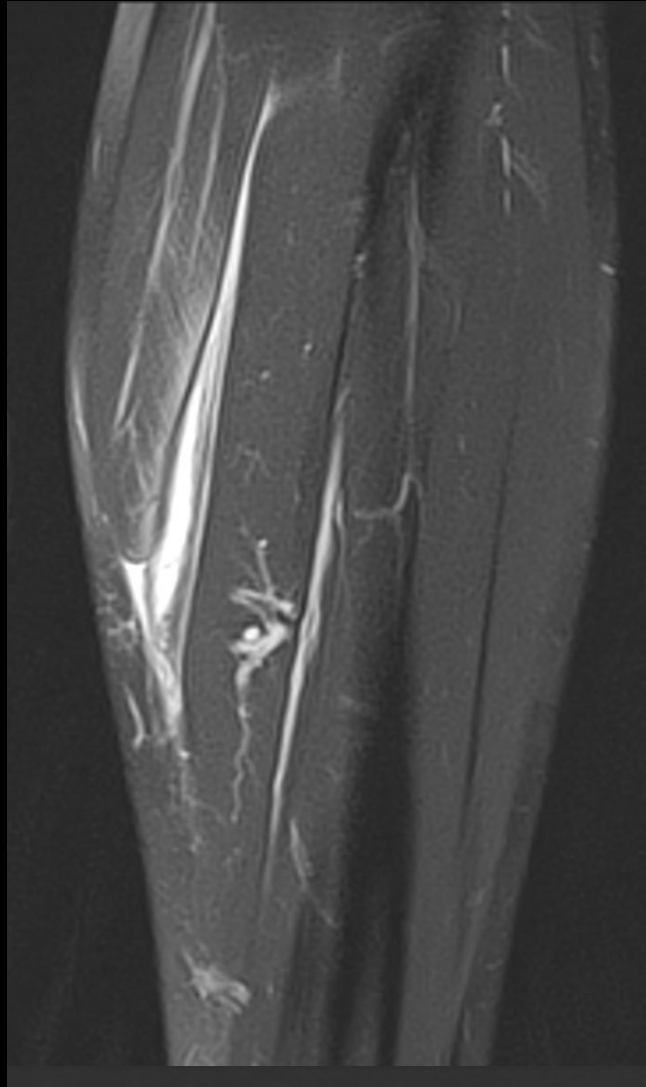

Le Tennis leg.

Espace virtuel du plantaire grêle

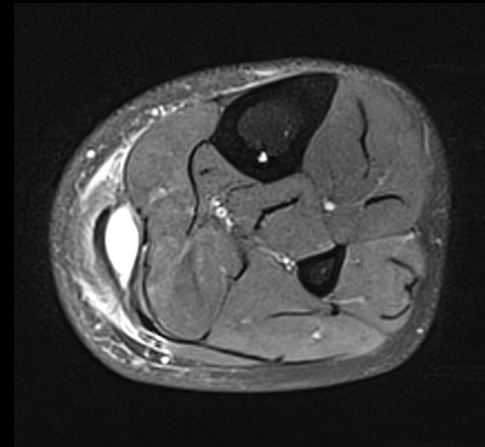
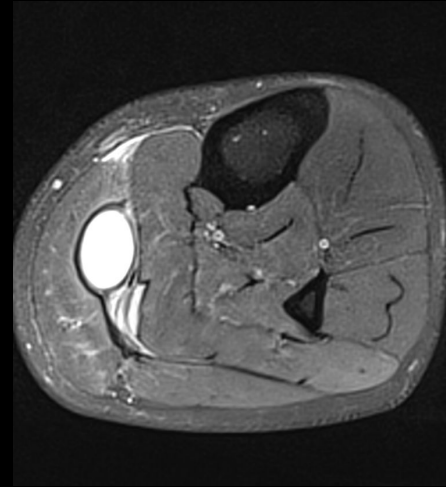
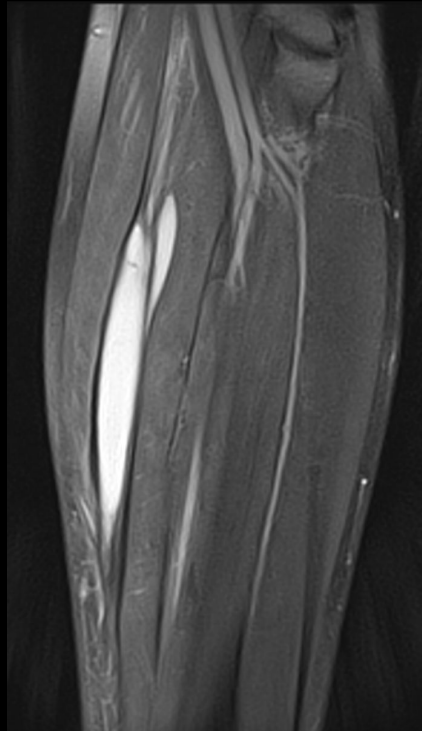
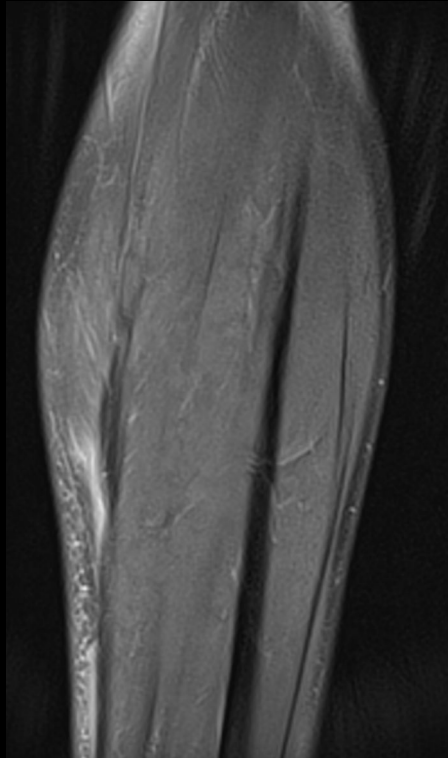
Le Tennis leg.



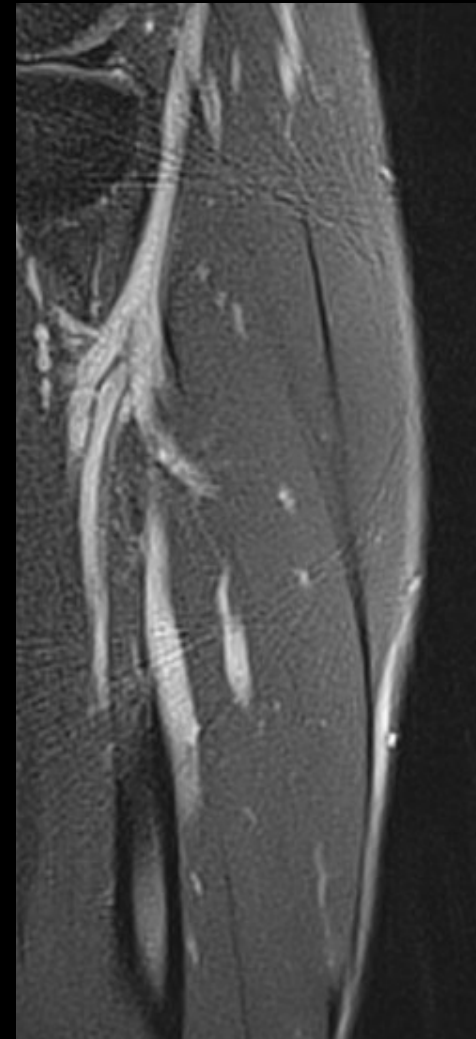
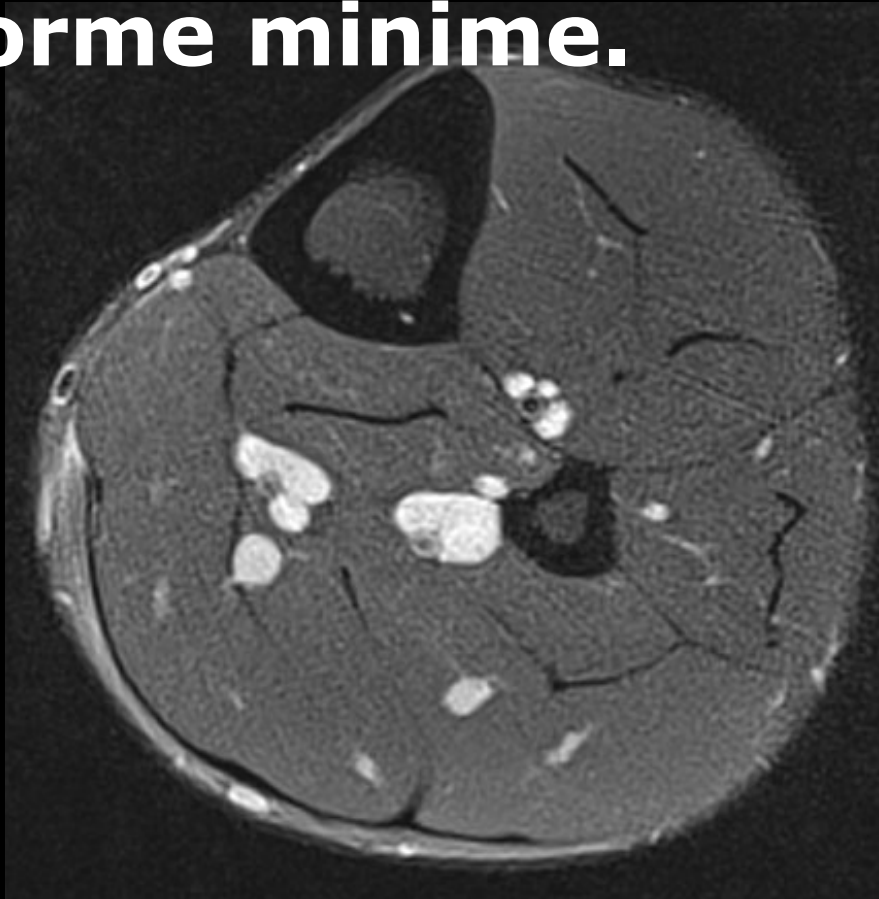
18
D6
2D
ITI
3
SC
C6

Tennis leg.



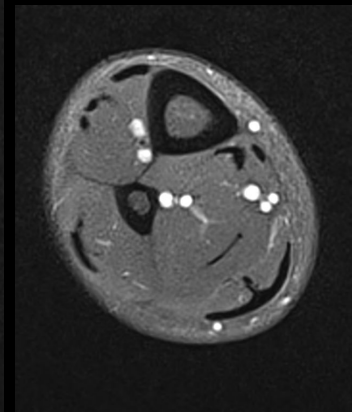
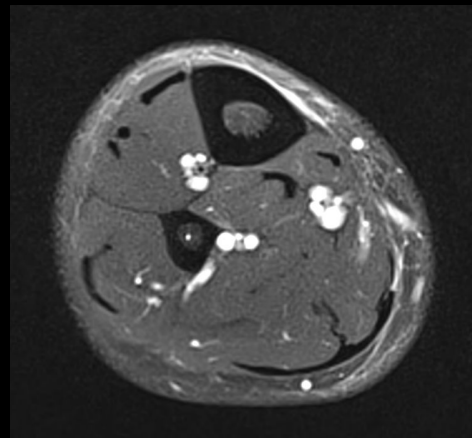
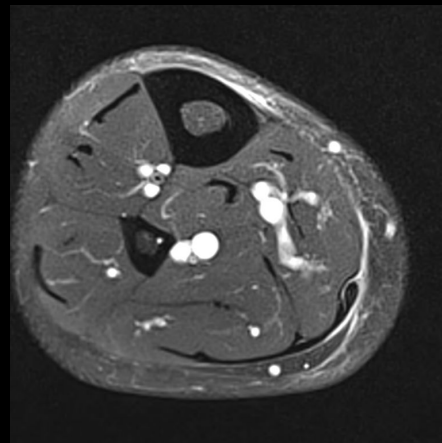
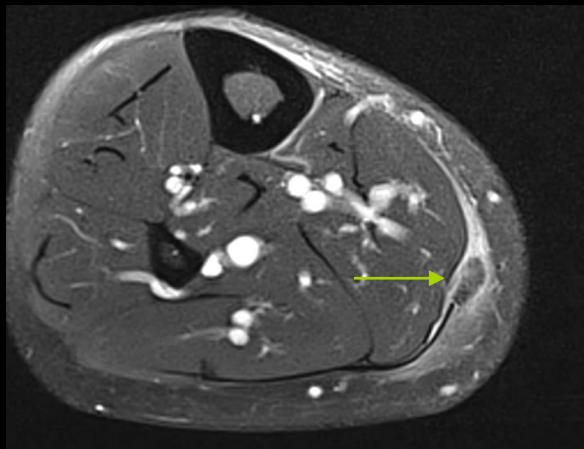
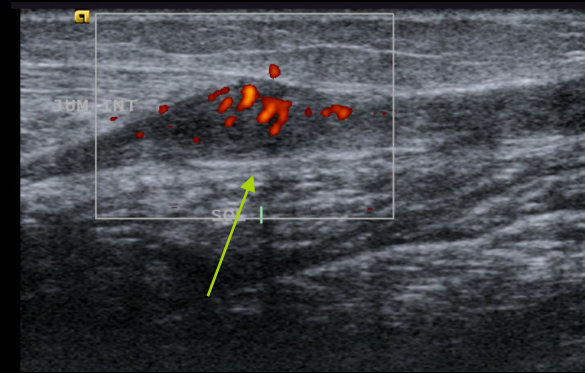
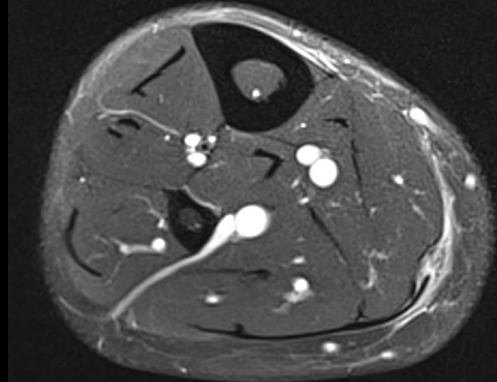
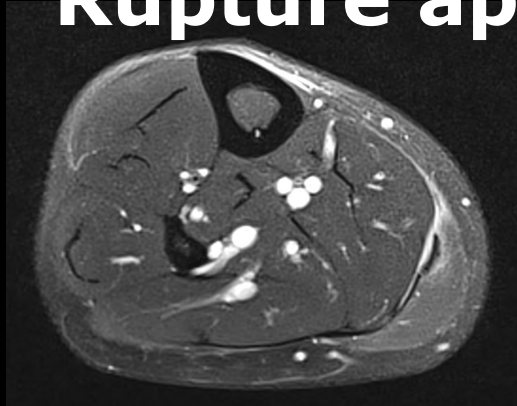
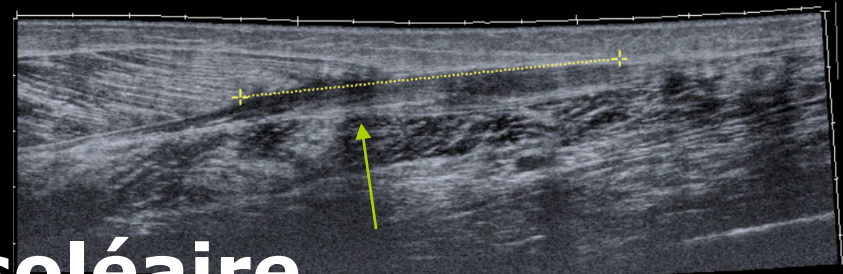
Tennis leg.

Forme minime.



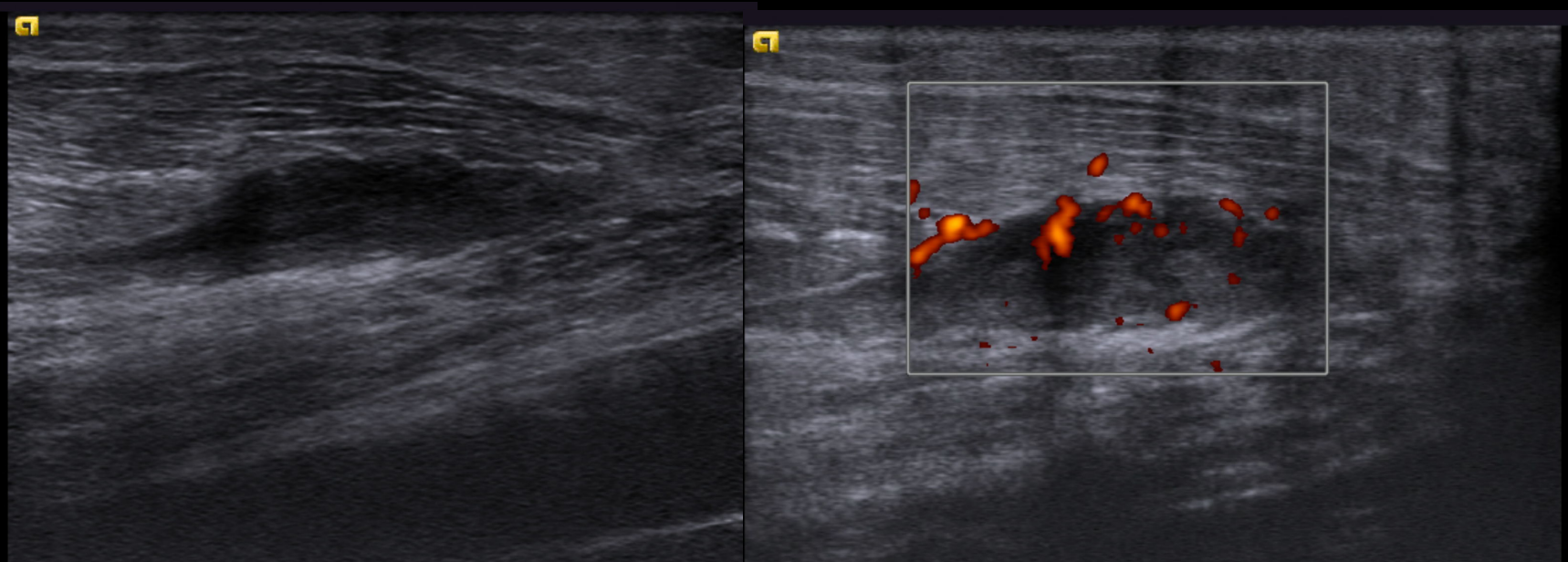
Tennis leg.

Rupture aponévrose soléaire

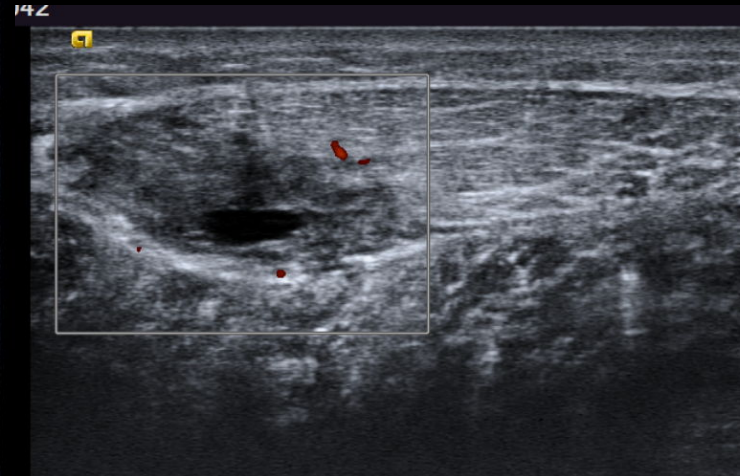
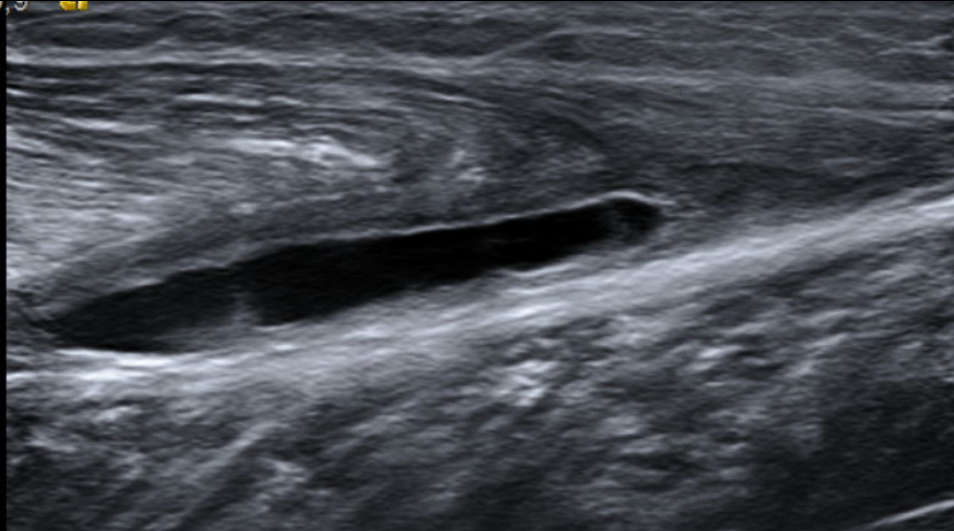


Tennis leg.

Hyperhémie

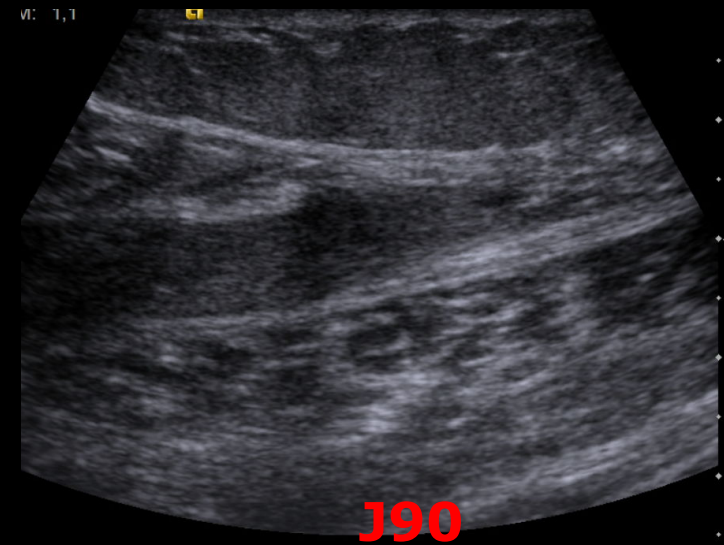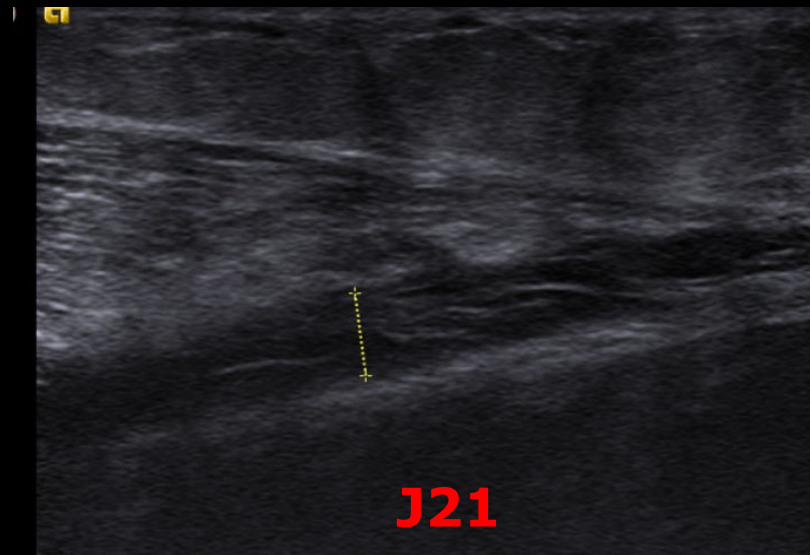
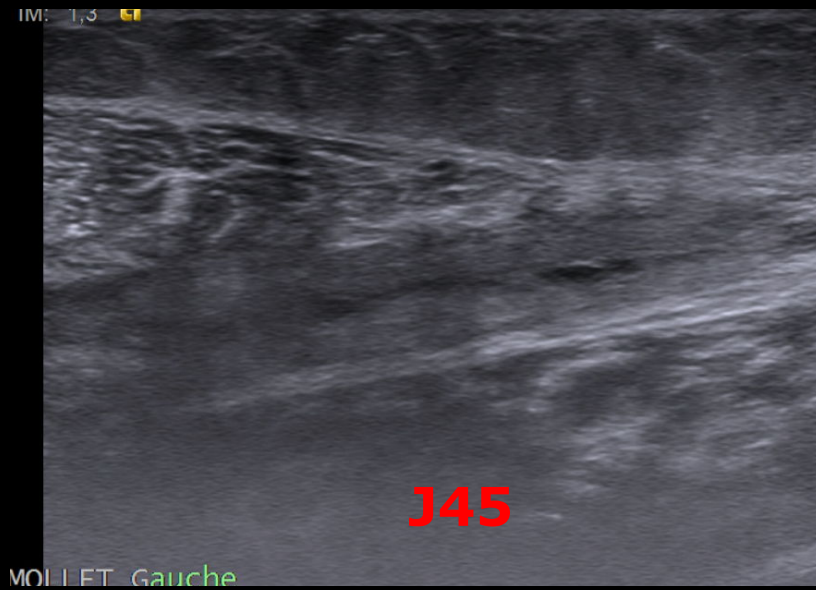
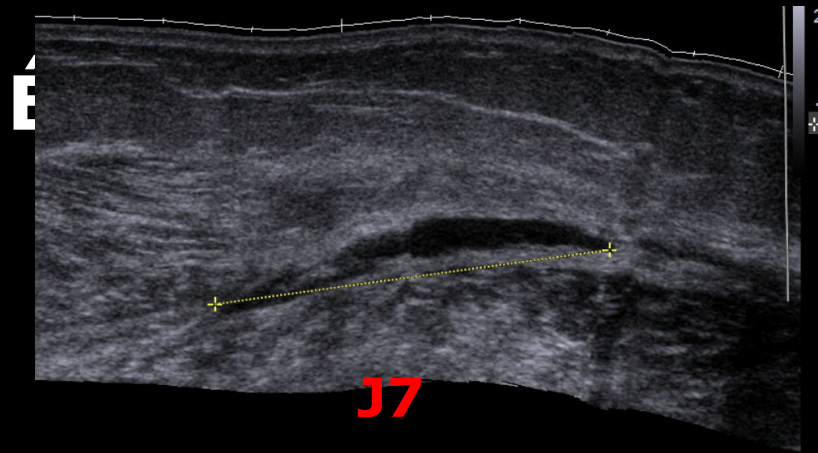


Tennis leg.

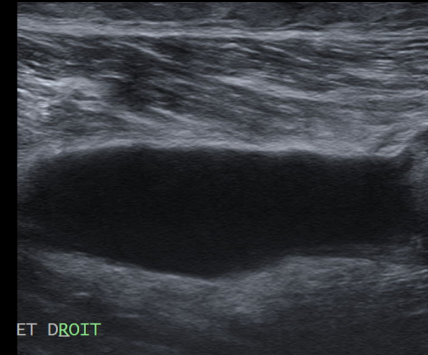
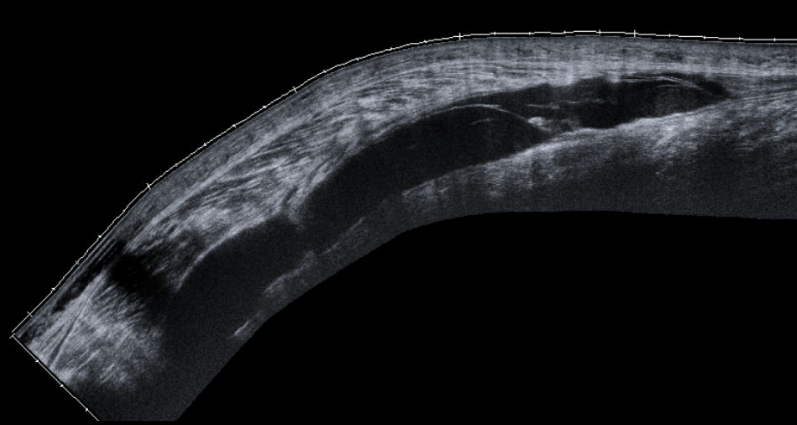


Évolution à un mois d'un tennis leg de moyenne sévérité.

Tennis leg.

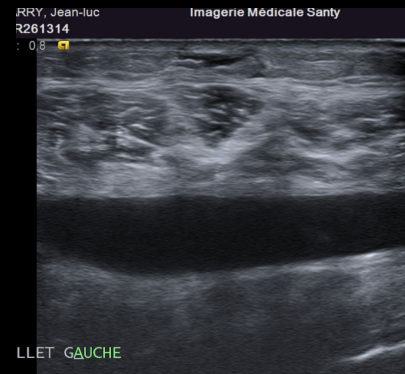
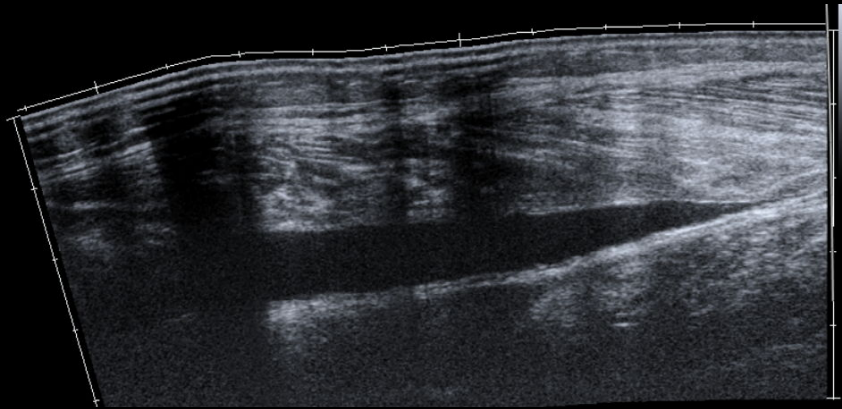


Tennis leg.



ET DROIT

Aline R



RRY, Jean-luc
R261314
: 0.8

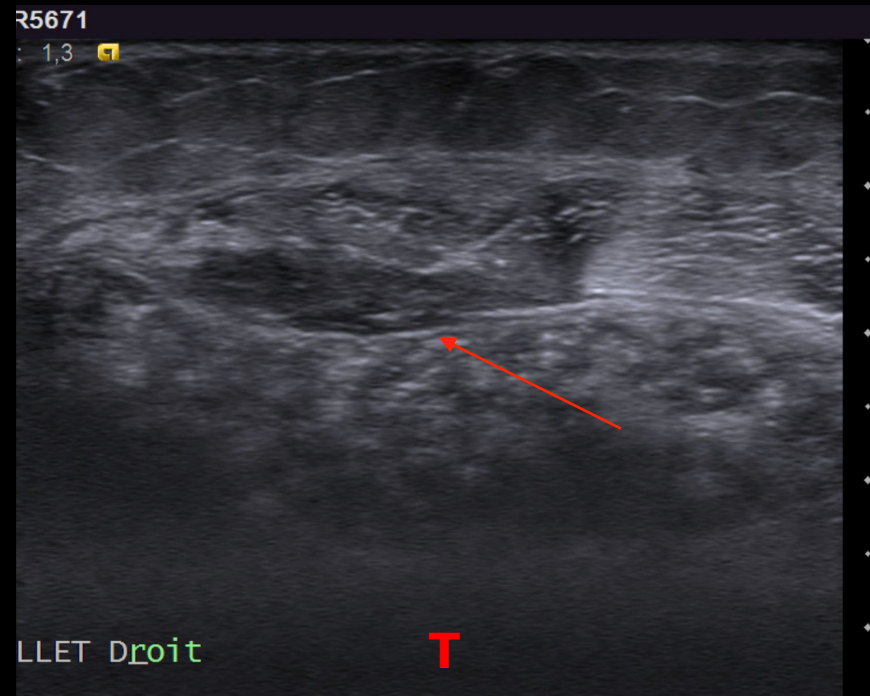
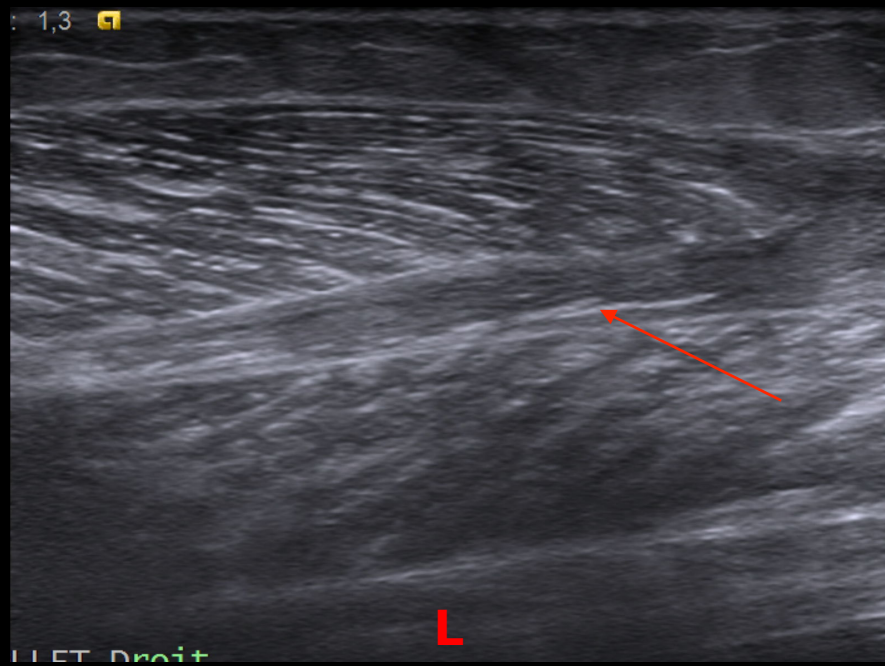
Imagerie Médicale Santy

LLLET GAUCHE

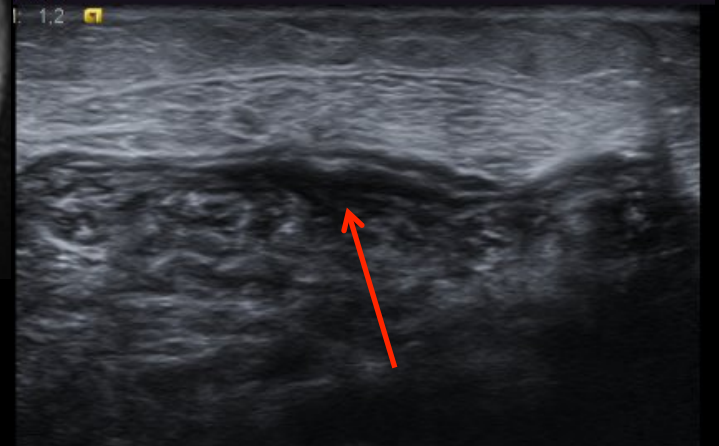
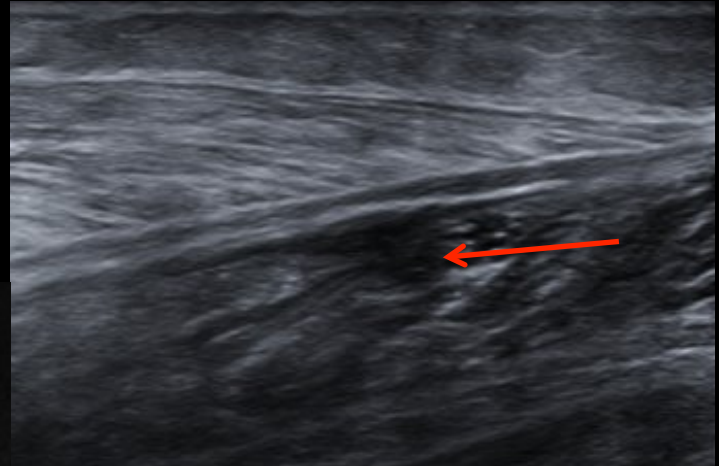
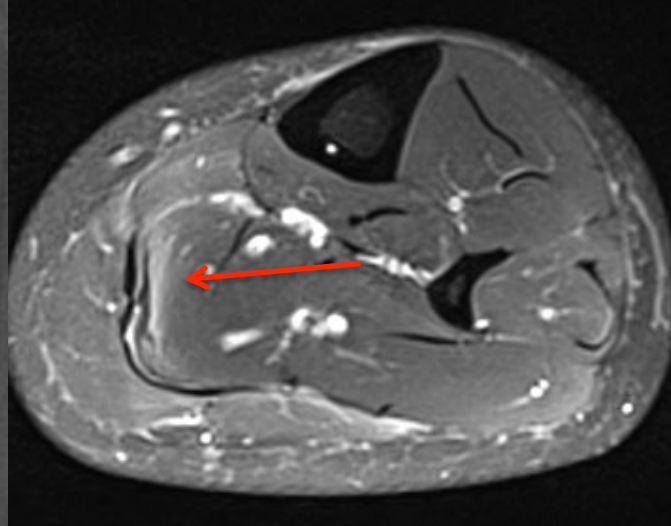
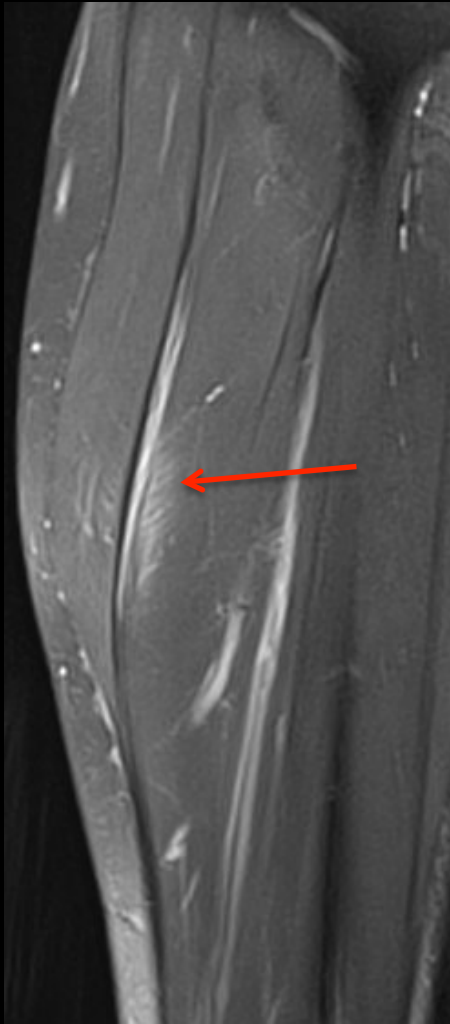Tennis leg bilatéral avec décollement proximal à gauche.

Tennis leg.

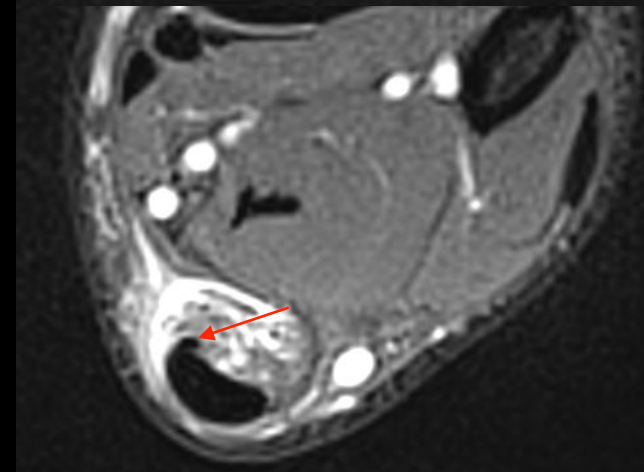
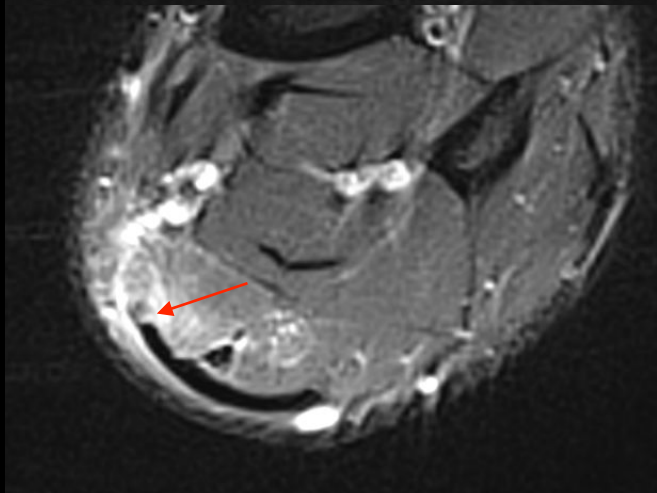
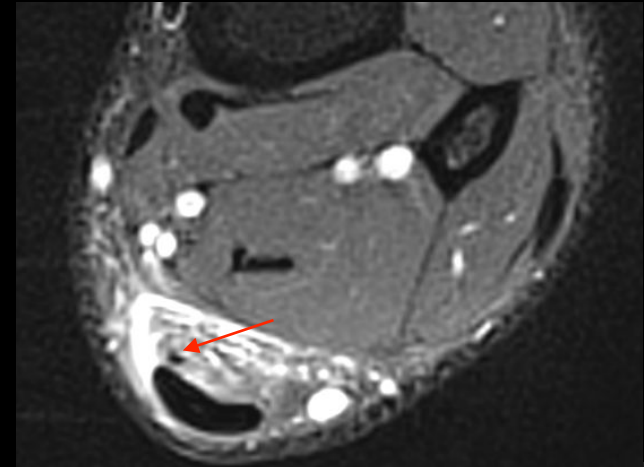
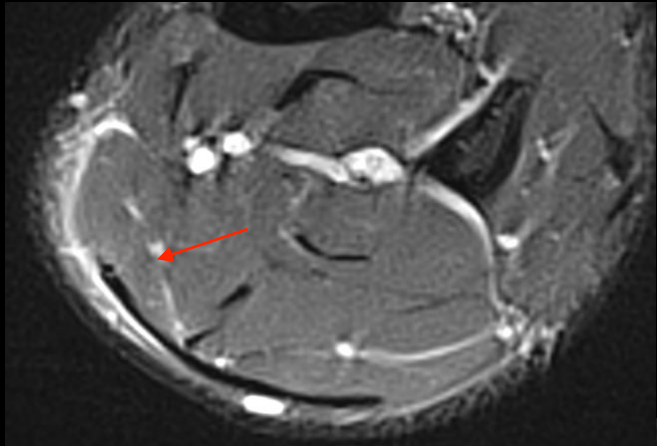
Évolution fibreuse



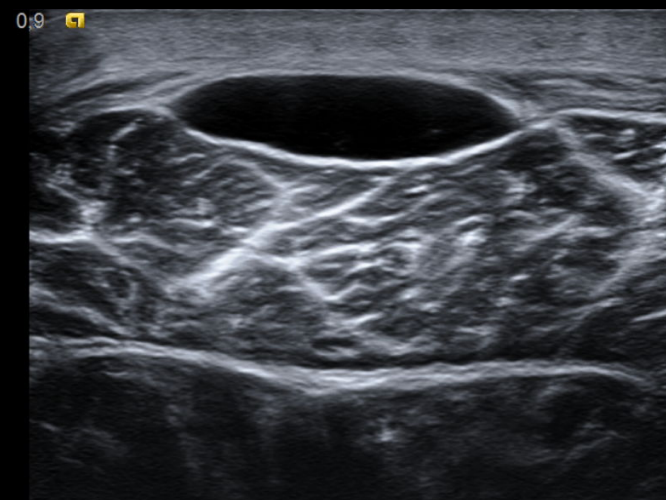
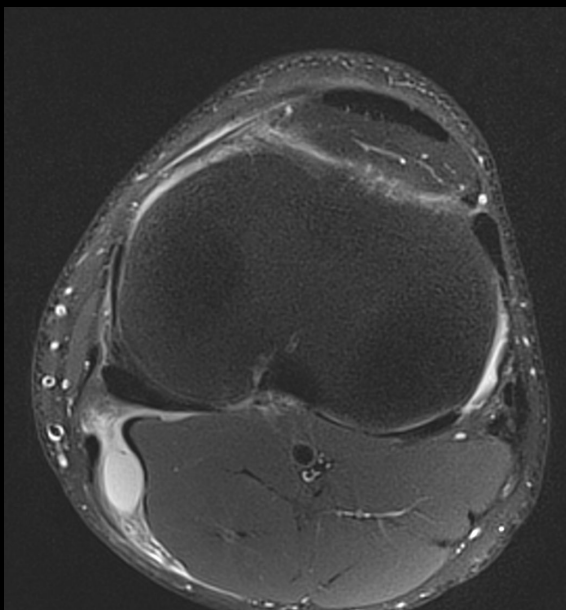
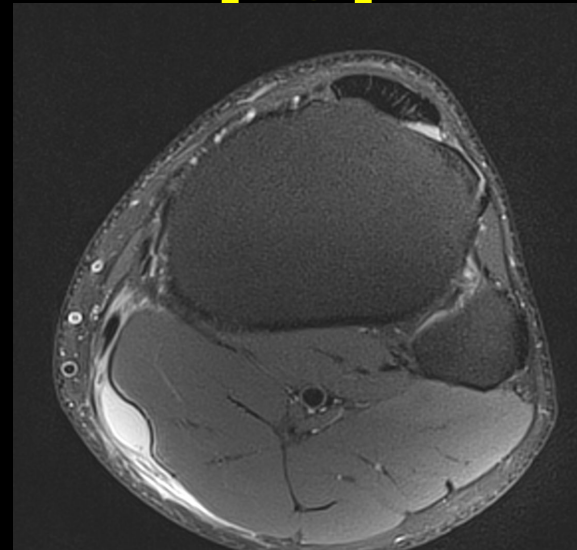
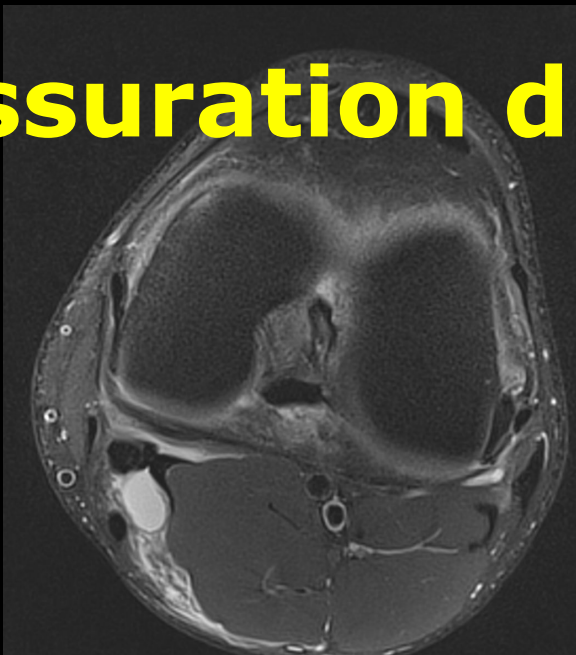
Tennis leg + DMA soléaire.



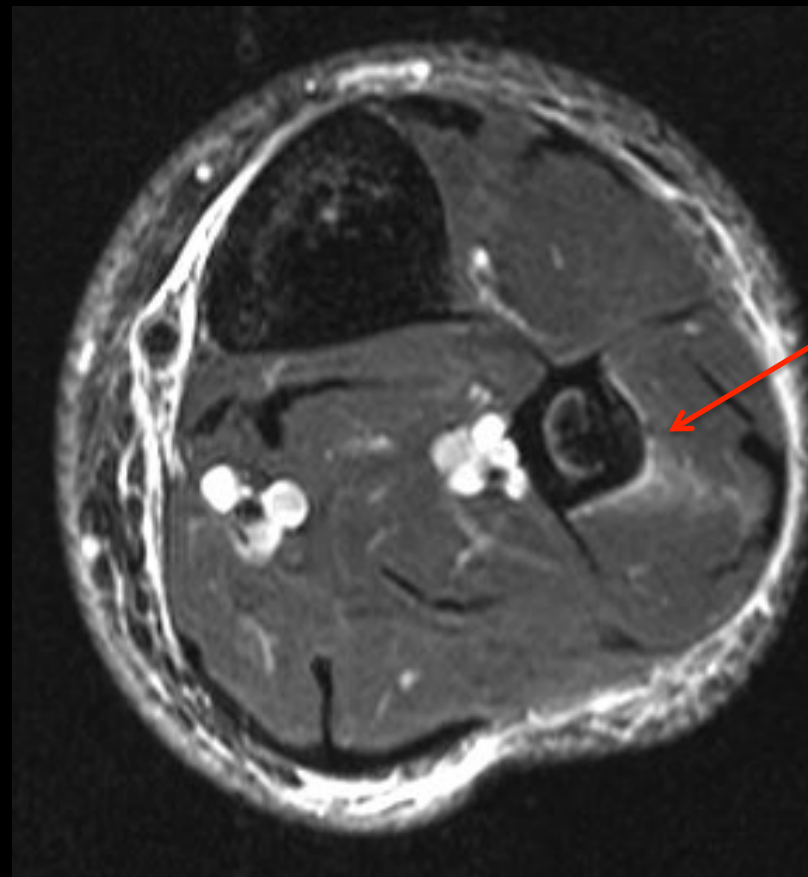
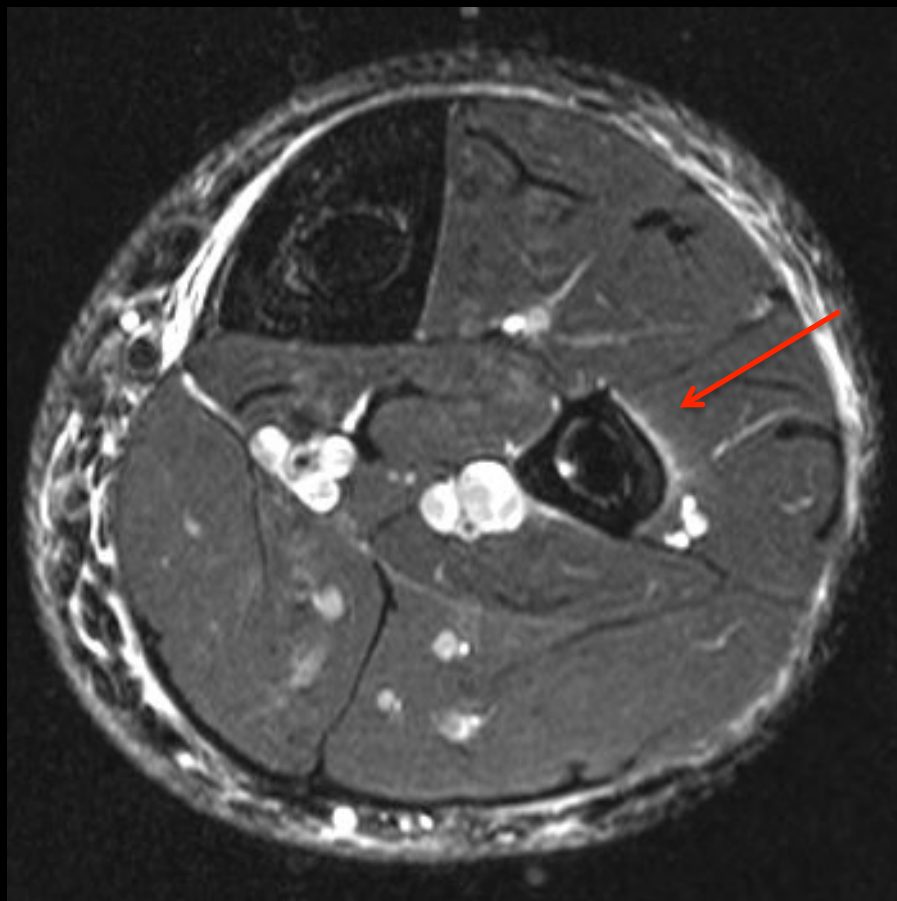
Plantaire grêle.



Fissuration d'un kyste poplité.

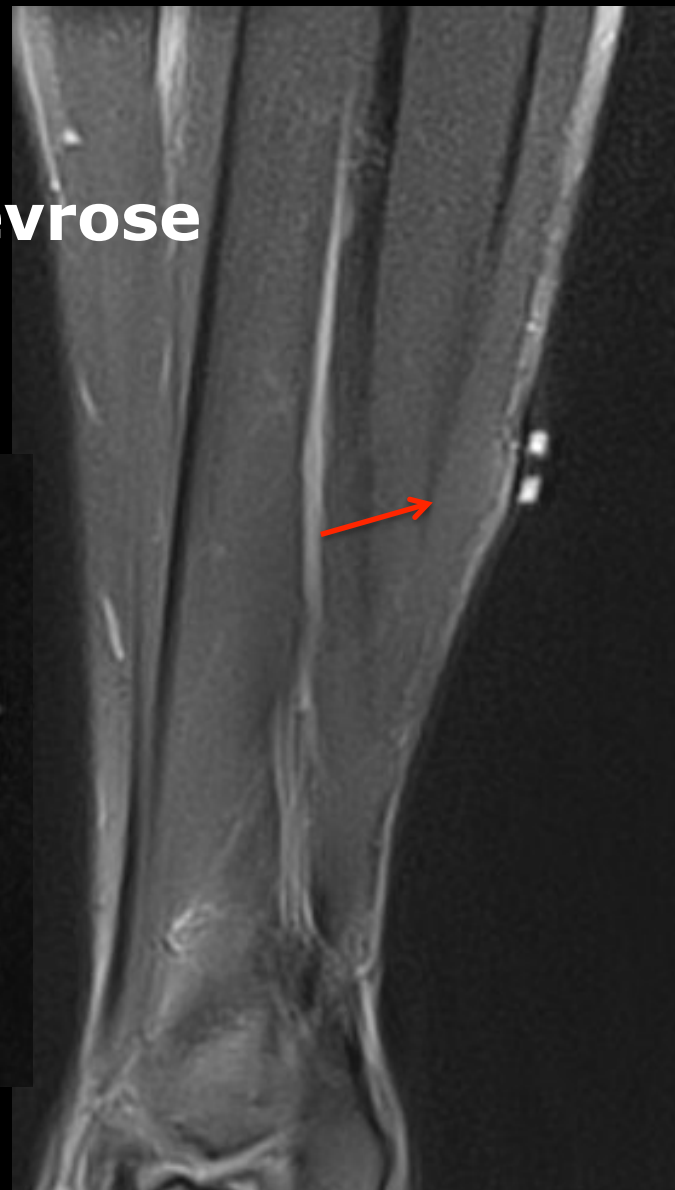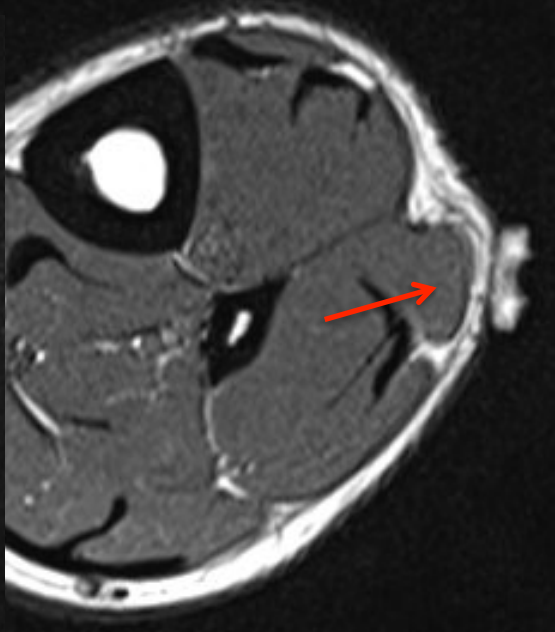
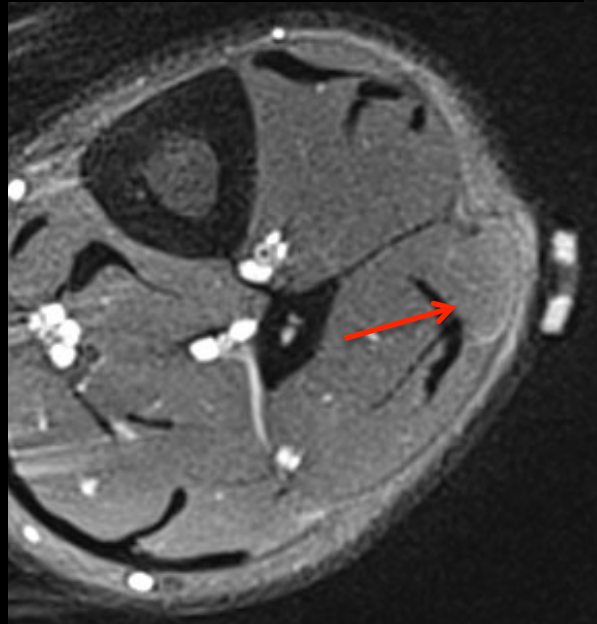


Fissure de stress.



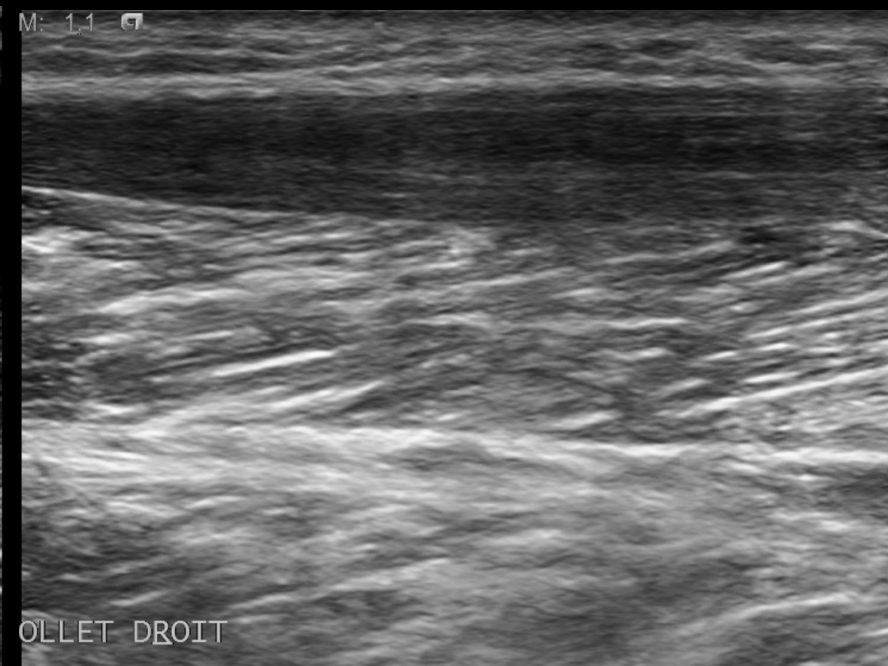
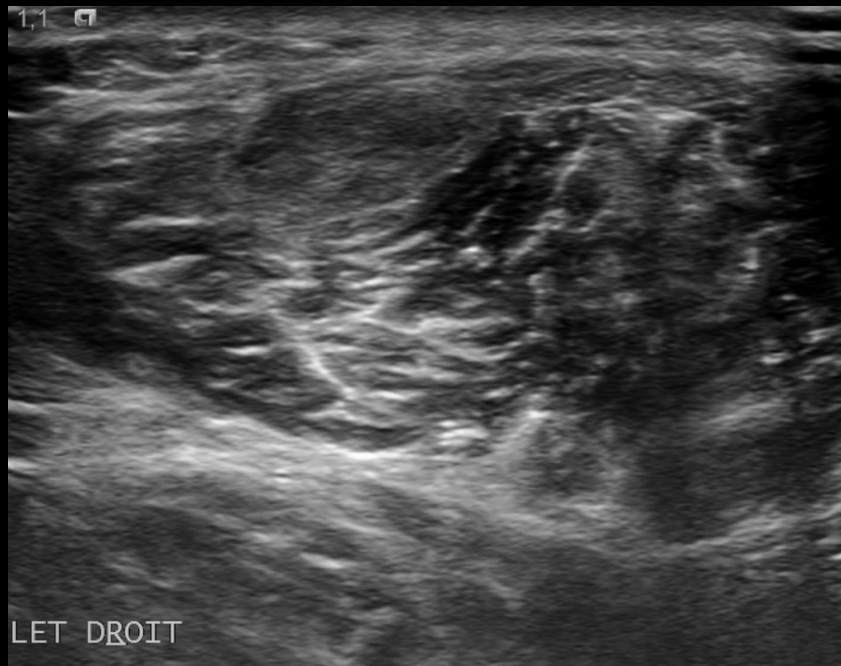Long fibulaire.

Séquelles de rupture de l'aponévrose superficielle.



Soléaire

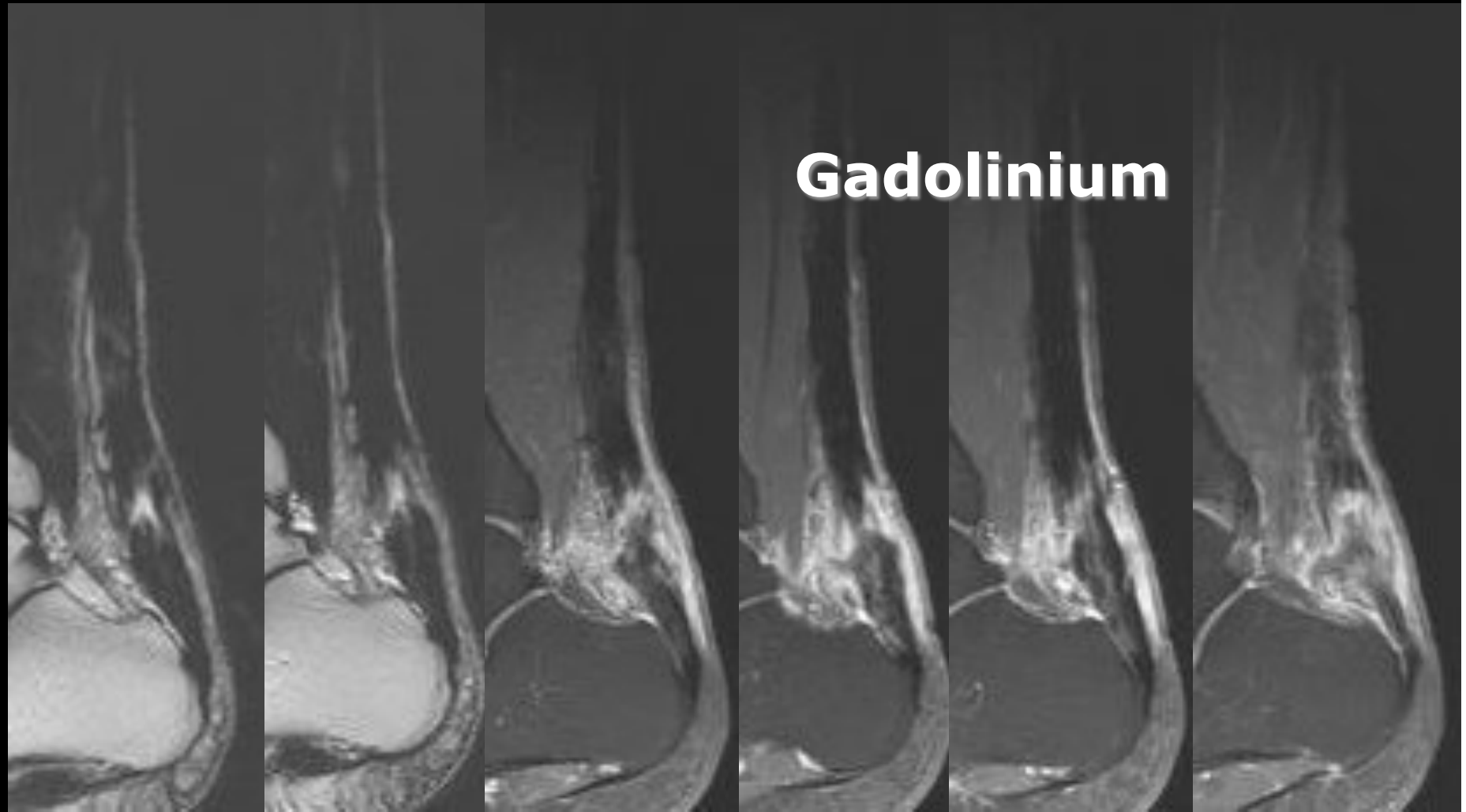
Cicatrice fibreuse.



Les ruptures du tendon calcanéen.

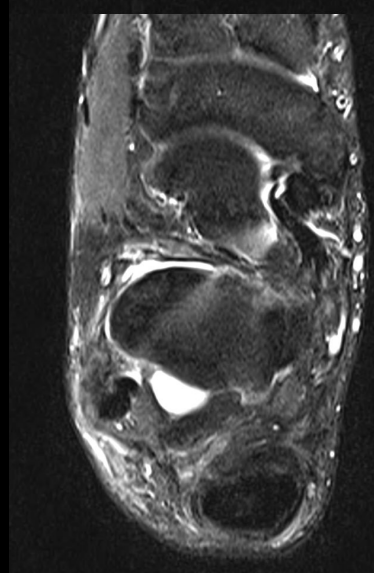
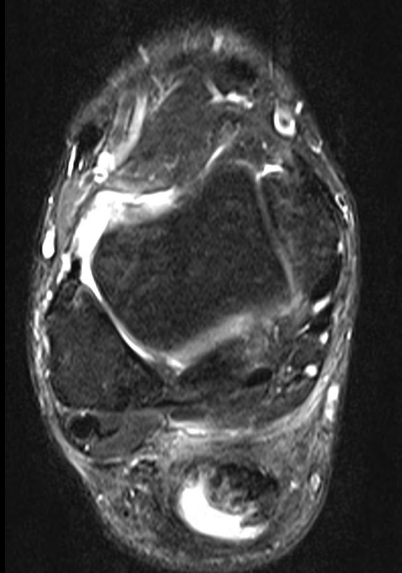
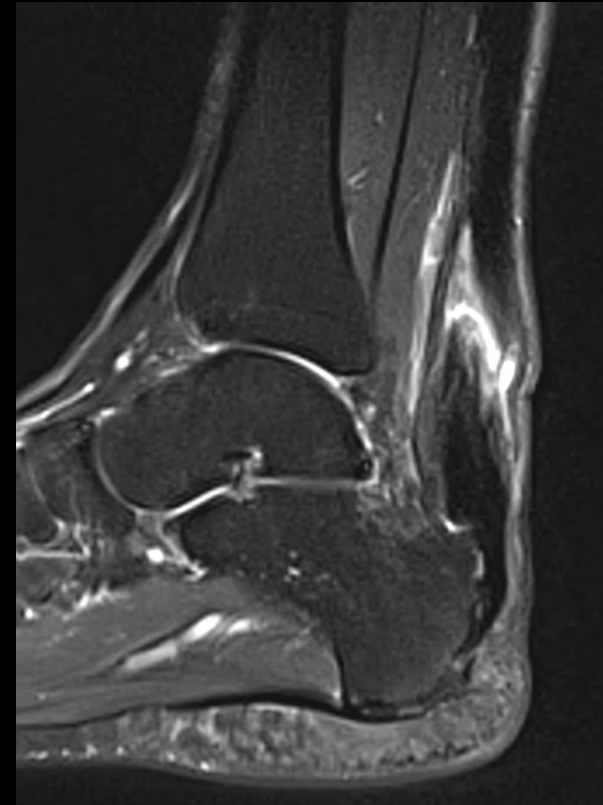
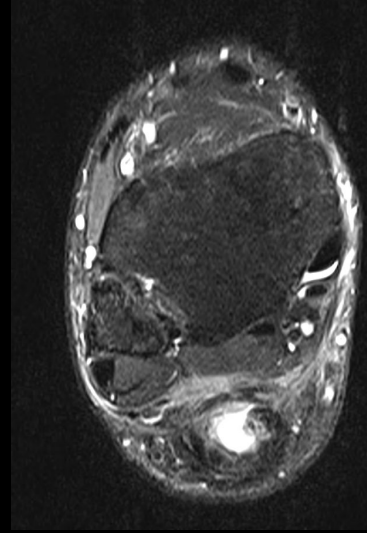
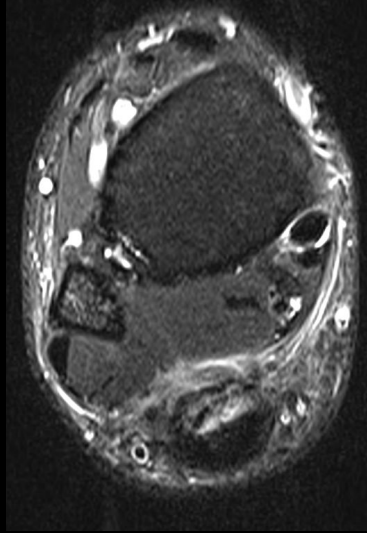
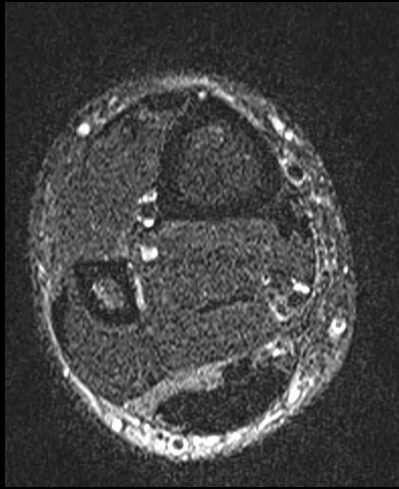
- **Totale**
- **Partielle**
- **Tendinite traumatique : péritendinite**

Rupture du tendon calcanéen

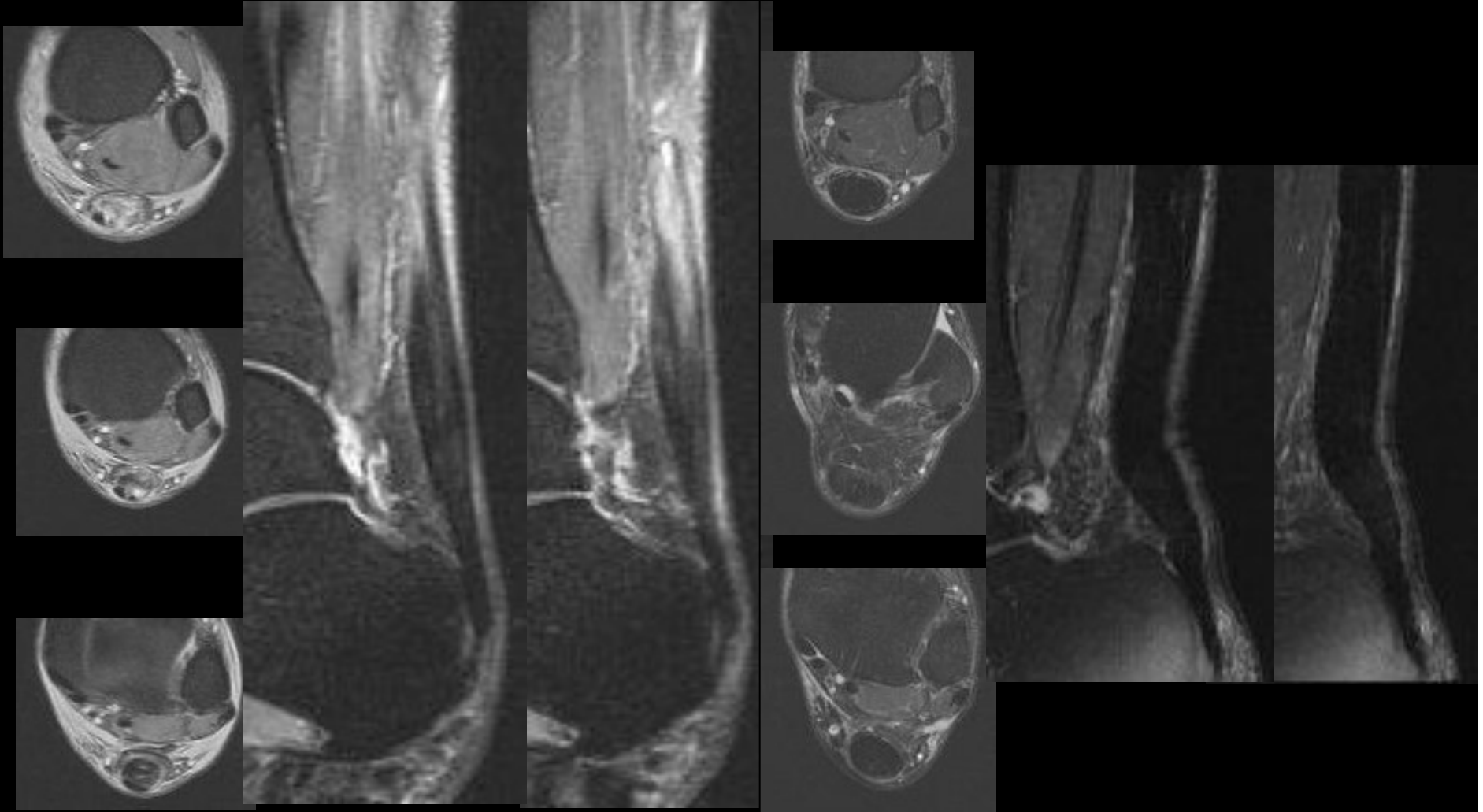


TA13

Rupture du tendon calcanéen.

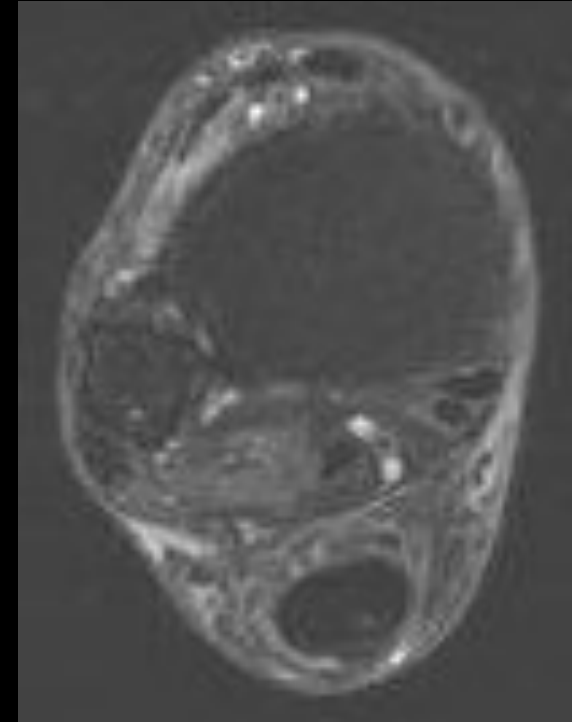
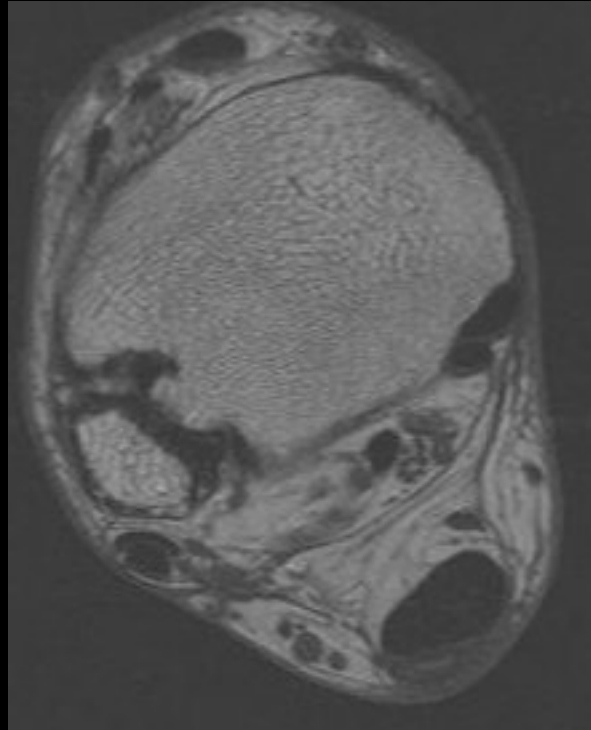
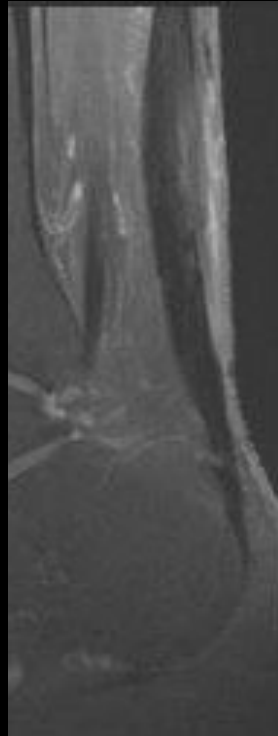
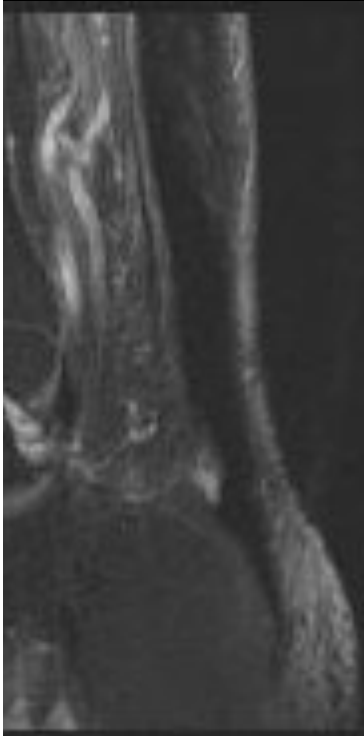
Rupture du tendon calcanéen.

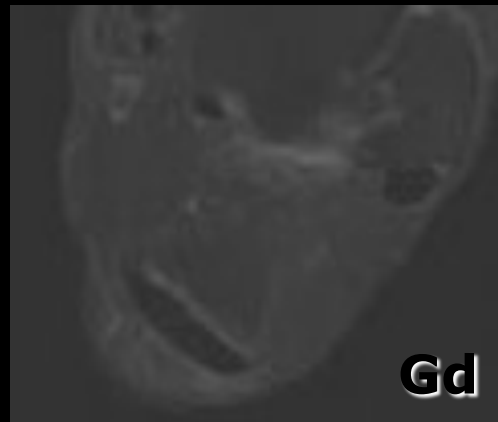
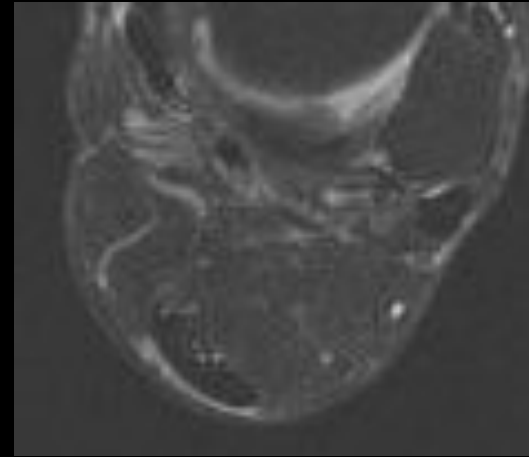
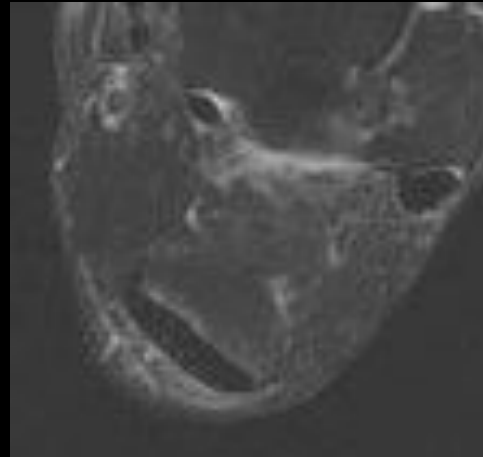
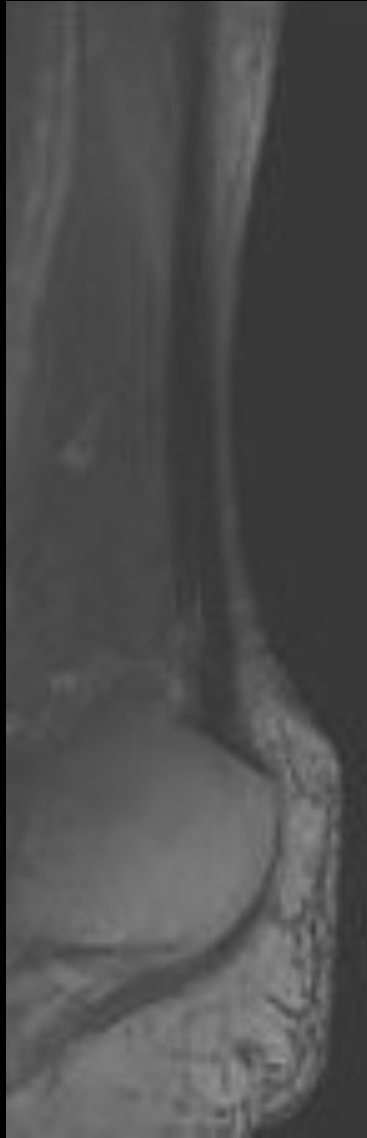

Traitement conservateur

Atteinte partielle de la jonction myo-tendineuse.



Péritendinite.



Conclusion

- **Difficulté en échographie des DMA centrales du soléaire.**
- **Participation possible du tendon calcanéen aux ruptures de l'aponévrose du gastrocnémien médial.**